

## 2D Reduced Field of View Spiral Inversion Recovery Sequence for High Resolution Multiple Inversion Time Imaging in a Single Breath Hold

Galen D Reed<sup>1</sup>, Reeve Ingle<sup>1</sup>, Ken O Johnson<sup>1</sup>, Juan M Santos<sup>1</sup>, Bob S Hu<sup>2</sup>, and William R Overall<sup>1</sup>

<sup>1</sup>Heartvista, Menlo Park, California, United States, <sup>2</sup>Cardiology, Palo Alto Medical Foundation, Menlo Park, California, United States

### Target Audience

MRI physicists working in cardiovascular magnetic resonance, cardiologists

### Purpose

Inversion recovery-prepared segmented gradient echo imaging has widespread use in the delineation of scar tissue from healthy myocardium after ischemic injury (1,2). The short readout time required with segmented acquisitions to prevent image artifacts confound the encoding of high resolution images within reasonable breath hold durations. By combining the efficiency of parallel spiral imaging with a 2-dimensional field-of-view reduction, we designed a sequence that acquires 1.7 mm in-plane resolution images in a 7 heartbeat breath hold. The short acquisition window enabled repeating the sequence to obtain a series of images with different inversion times.

### Methods

Figure 1a shows a diagram of the imaging sequence. An adiabatic inversion was used for T1 contrast. In order to increase the spatial resolution without increasing breath hold duration, a two dimensional circular outer volume suppression (OVS) was utilized which consisted of a BIR-4 90 followed by a selective spiral 2D flip back pulse (3). After the OVS, a single interleave of a dual-density spiral (7.7 mm inner resolution, 1.7 mm outer resolution) was acquired NTI = 20 times. The sequence used an  $10^0$  water-selective spectral spatial excitation. Each heartbeat corresponded to a different interleave so that each image of the cardiac cycle could be mapped to a different inversion time (4,5). Each TI image was reconstructed with a non-Cartesian SPIRiT iterative algorithm (6). After informed consent, patient images were acquired 4 minutes post Gd (Multihance) administration on a GE 1.5 T scanner using an 8 channel cardiac coil. The HeartVista RTHawk platform (7) was used for all sequence programming.

### Results

Figure 1b shows the 4 out of a total of 20 images acquired at varying inversion times. The inversion recovery contrast is preserved with the 2D OVS, and a null-time of the myocardium was identical with and without OVS (Figure 1c).

### Discussion / Conclusion

The combination of 2D FOV reduction with the under sampled spiral readout was applied for high resolution inversion-recovery myocardial imaging. The reduced number of total required encodes facilitates high resolution T1-weighted imaging within short breath hold durations and could be utilized for TI calibration or direct multi-slice imaging of multiple TI values.

### References

- 1) R. J. Kim, D. S. Fieno, T. B. Parrish, et al. *Circulation*. 1999;100:1992-2002.
- 2) O. P. Simonetti, R. J. Kim, D. S. Fieno, et al. *Radiology*. 2001;218:215-233.
- 3) T. B. Smith and K. S. Nayak. *Magn Reson Med*. 2012;67(5):1316-1323.
- 4) A Gupta, V. S. Lee, Y-C Chung, et al. *Radiology*. 2004;223:921-926.
- 5) J.S. Detsky, J.A. Stainsby, R. Vijayaraghavan, et al. *Magn Reson Med*. 2007;58(12):3651-372.
- 6) M. Lustig and J. M. Pauly. *Magn Reson Med*. 2010;64(2):457-471.
- 7) J. M. Santos, G. A. Wright, and J. M. Pauly. *Conf Proc IEEE Eng Med Biol Soc*. 2004;2:1048-51

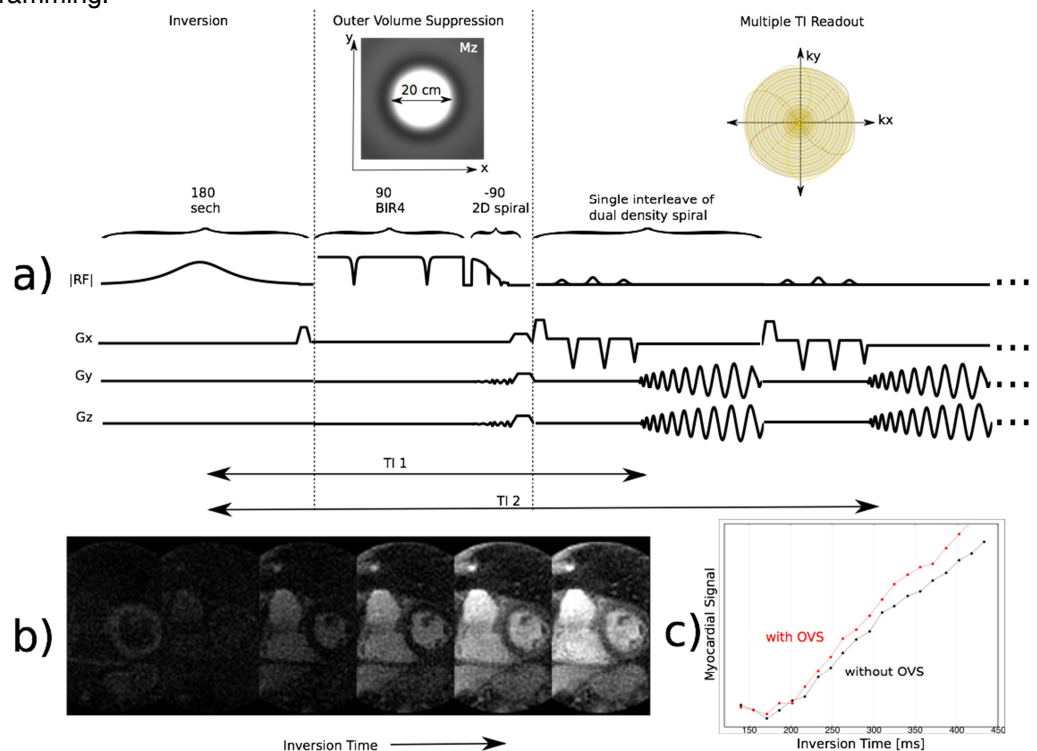


Figure 1: a) The sequence used an adiabatic inversion followed by 2D outer volume suppression and cine-style repeated acquisition of a single interleave per heartbeat. b) images acquired at multiple TI values 4 minutes after Gd administration. c) myocardium signal as a function of TI with and without OVS