

Hemodynamic variations and the direction of ophthalmic artery flow in patients with internal carotid artery stenosis before and after stenting: A DSC MRI study

Pei-Shan Ho¹, Ting-Yu Chang², Kuo-Lun Huang², Feng-Xian Yan^{1,3}, Ho-Fai Wong⁴, Tsong-Hai Lee², and Ho-Ling Liu^{1,4}

¹Medical Imaging and Radiological Sciences, Chang Gung University, Taoyuan, Taiwan, ²Neurology and Stroke Center, Chang Gung Memorial Hospital and Chang Gung University College of Medicine, Taoyuan, Taiwan, ³Radiology, Taipei Medical University - Shuang Ho Hospital, New Taipei City, Taiwan, ⁴Medical Imaging and Intervention, Chang Gung Memorial Hospital, Taoyuan, Taiwan

Introduction

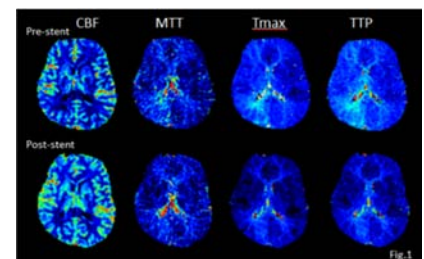
High-grade internal carotid artery (ICA) stenosis often accompanies reversed ophthalmic artery (OA) flow, which was compensated by external carotid artery (1), but its potential clinical meaning stay implicit. It is critical that the earlier diagnosis and treatment of stenosis can prevent individuals from high risk of stroke (2). Perfusion MRI utilizing the dynamic susceptibility contrast (DSC) method has widely been implemented to assess the microvascular flow in the brain (3). Hemodynamic parameters such as cerebral blood flow (CBF), time to maximum (Tmax), mean transit time (MTT) and time to peak (TTP) can be derived from DSC-MRI (4). However, the quantified comparison between OA flow forward and reversed patient groups was not documented. This study compared these important physiological in patients with unilateral ICA stenosis before and after stent surgery between OA flow forward and reversed by using DSC MRI.

Methods

The study consisted of 51 patients diagnosed as unilateral internal carotid artery (ICA), 18 patients (age: 69.3±7.9, 15 males and 3 females) accompanied with OA flow reversed in ipsilateral and 33 patients (age: 68.5±7.3, 30 males and 3 females) with OA flow forward. The direction of OA flow was detected by color-coded carotid duplex ultrasound. Subjects were scanned twice (one week before and one week after stenting) at a 1.5T Philips Intera MRI scanner. DSC-fMRI were acquired using a T2*-weighted single-shot gradient-echo EPI sequence (TR/TE/FA = 1500ms/40ms/90°, in-plane matrix = 128 x 128, slice thickness = 5mm, 20 slices, 60 dynamics). DSC data were analyzed by the block-circulant singular-value decomposition (bSVD) method. For each subject, arterial input function (AIF) was selected from whose middle cerebral artery (MCA) by the average of five voxel points. Then, the deconvolution process of bSVD method generates CBF, Tmax, MTT and TTP maps. A territory of MCA ROI was manual drawn carefully by a neurologist, and were normalized to the coordinates for each subjects. For quantitative comparisons, another ROI of occipital territory was implemented as a reference ROI in CBF maps. Statistics analysis were compared using two way ANOVA which include two factors of lateral (ipsi- and con-lateral) and period (pre- and post-stenting) at significant level of $p < 0.05$.

Results

Figure 1 shows that the parameter maps of a typical subject with severe right side ICA stenosis accompanied reversed OA flow before and after stenting. The MTT, Tmax and TTP maps illustrate higher relative value at right side than left side before stenting. In contrast, there were improved MTT, Tmax and TTP after treatment. The table shows the averages of parameter maps in MCA territory in forward group and reversed group. In reversed group, there were much more differences between ipsilateral and contralateral in Tmax, MTT, and TTP while pre-stenting ($p < 0.0005$). Moreover, the generally improvement of parameter values was found after stent surgery. Figure 2 exhibits the group results of two way ANOVA analysis. The parameters with cross indicate interaction between two factors of lateral and period. No interaction was



demonstrated on MTT values in OA flow forward patients and nCBF values in reversed patients, but they displayed significant difference between pre- and post-stenting. For the interaction indicators, only Tmax values were significantly higher while pre-stenting in ipsilateral for those OA flow forward patients. However, significantly higher value was found in Tmax and MTT while pre-stenting in ipsilateral, and while pre-stenting, ipsilateral were significantly higher than contralateral in Tmax, MTT and TTP values.

Conclusion

The study is aimed to investigate the indicative parameter maps of perfusion DSC MRI in subjects who suffered from unilateral ICA stenosis. Contrary to patients with OA flow forward, patients with OA flow reversed have increased mean transit time as well as the arrival time delay before stent surgery. The effective recovery was detected after carotid stent replacement.

Reference

1. Vernieri et al. Stroke 2001;32:1552-1558.
2. Tsai et al. 2013;20:564-570.
3. Ostergaard et al. Magn Reson Med 1996;36:726-730.
4. Ona Wu et al. Mang Reson Med 2003;50:164-174.

	Forward (n=33)				Reversed (n=18)			
	Pre		Post		Pre		Post	
	ipsi	con	ipsi	con	ipsi	con	ipsi	con
nCBF	0.86±0.1	0.84±0.1	0.87±0.1	0.85±0.1	0.87±0.1	0.89±0.1	0.93±0.1*	0.91±0.1
Tmax (s)	3.24±1.8	2.95±1.8	2.25±0.8*	2.48±0.9*	4.26±2.6*	2.51±2.0	2.54±1.1*	2.20±0.9
MTT (s)	5.20±0.8	5.14±0.8	4.78±0.5*	4.86±0.6*	5.71±1.0*	4.92±0.5	5.01±0.6*	4.88±0.6
TTP (s)	28.31±3.4	28.05±3.6	27.69±3.0	27.96±3.1	29.07±5.5*	26.98±5.5	27.32±3.4	26.95±3.6

* Significant difference between ipsi- and contralateral, $p < 0.0005$.
* significant difference between pre- and post-stenting, $p < 0.05$.

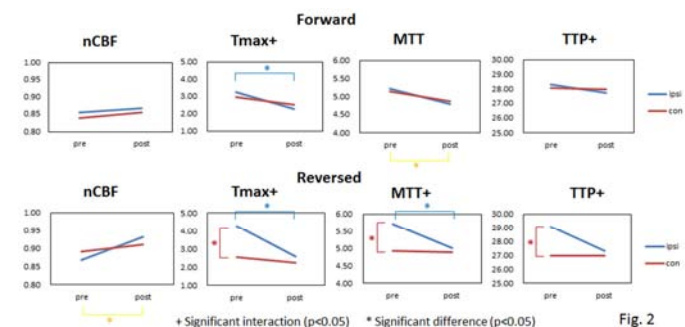


Fig. 2