

Working memory deficit in children treated for cerebellar medulloblastoma: An fMRI study

Duc Ha Hoang¹, Anne Pagnier², Emilie Cousin³, Karine Guichardet², Isabelle Schiff², Fanny Dubois-Teklali², and Alexandre Krainik⁴

¹Grenoble Institute of Neurosciences, Grenoble, France, ²Department of Pediatrics - Grenoble University Hospital, Grenoble, France, ³Laboratory of Psychology and Neurocognition - University Pierre Mendès, Grenoble, France, ⁴Department of Neuroradiology and MRI - Grenoble University Hospital, Grenoble, France

Backgrounds and Purposes

Medulloblastomas are the most common malignant brain tumors in childhood. Children treated for a cerebellar medulloblastoma demonstrated cognitive disorders in working memory (WM), especially visuospatial WM, leading to an impairment of school performance.¹ The purpose of recent study is to describe the cerebellar involvement in specific cognitive deficits observed in children treated for cerebellar medulloblastoma.

Materials and Methods

Groups: Nine healthy volunteers children (11.1 ± 2.2 yo), were compared to 5 patients treated for cerebellar medulloblastoma (12.1 ± 0.6 yo). All subjects were native French speakers, right-handed, with a global IQ of 70-130. The patients were after 6 years of age (homogeneous population in terms of brain maturation) and at least six months after the end of all treatments. Healthy subjects have without any history of psychiatric, neurological or other major medical disorder.

Task Procedures: The participants were examined through 4 block-design 1-back tasks in the sensorial modality (visual/auditory) and the nature of information (verbal/nonverbal) during fMRI acquisitions. Each task consisted of 4 blocks and each block composed 7 stimuli. Each stimulus was presented for 2000 ms, followed by a delay of 3000 ms before the next trial. Subjects were instructed to be fast and accurate in their responses before the exam. Both accuracy and reaction time (RT) were collected for each response.

MRI Acquisitions: All MRI data were acquired on 1.5T Achieva MR Scanner (Philips Healthcare®) using a 8-channel head coils. fMRI scanning was performed with a gradient-echo/T2* weighted EPI method. Slice thickness: 4 mm; voxel size: $4 \times 4 \times 4$ mm; 256 mm field of view; main sequence parameters: TR=5 s, TE=50 ms, flip angle=77°, 56 dynamics. Finally, a 3D T1-weighted was acquired (FOV: 256 mm; resolution: $1 \times 1 \times 1$ mm; 128 axial spiral slices).

Data Analysis: Reaction time and accuracy was recorded for each subject in ANOVA for behavioral performance. Standard image reconstruction, preprocessing and statistical analyses were performed using the Statistical Parametric Mapping (SPM8) and the Spatially Unbiased Infra-tentorial Template (SUIT)² for viewing cerebellar topography with BOLD activations.

Results

In the healthy subjects group: the sensory modality activated bilaterally occipital cortex during visual stimuli presentation and superior temporal gyrus during auditory tasks; the verbal tasks activated bilaterally middle temporal gyrus with left-side predominance whereas the nonverbal presentation activated the occipital cortex with right-side predominance; greater BOLD activations were found in the left posterior cerebellar lobe for nonverbal vs. verbal contrast and they were presented in this region for visual vs. auditory contrast (figure 1).

In patients group: 4/5 patients had a WM deficit following a resection of the left posterior cerebellar lobe (lobule VI-IX, Crus I and II) and inferior part of vermis; the only patient without WM deficit was the only one without cerebellar hemispheric resection (figure 2).

Conclusion

The cerebellum plays the same role in WM in children as that has been previously described in adults.³ The left posterior cerebellar lobe may involve the visuospatial WM⁴.

References: 1-Cantelmi. The lancet oncology 2008,9(6):569–576. 2-Diedrichsen. NeuroImage 2006,33(1):127–138; 3-Kirschen. Behavioural neurology 2010,23(1-2):51–63; 4-Hautzel. NeuroImage 2009,47(4):2073–2082

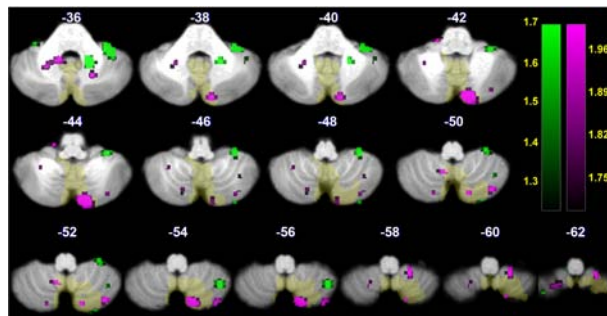


Fig.1: Activations of the cerebellar lobules were mapped onto axial sections of the spatially unbiased infratentorial template (SUIT) of the cerebellum² in our fMRI study of working memory in 5 children with medulloblastoma: Activation for visual vs. auditory contrast (green) and nonverbal vs. verbal contrast (purple).

Case	T1 WI MRI			Lesion site	WM deficit
	Axial	Coronal	Sagittal		
1				Left lobule VIIb, IX, Crus II and inf. part of vermis	Visuo-spatial sketchpad and phonological loop
2				Bila. lobule VIIb, VIII, IX, Crus II with left dominance and inf. part of vermis	Visuo-spatial sketchpad
3				Bila. lobule VIIb, VIII, IX, Crus III and inf. part of vermis	Visuo-spatial sketchpad
4				Left lobule VIIb, VIII and Crus II	Visuo-spatial sketchpad and phonological loop
5				Inf. part of vermis and without any hemisphere lesions	Without any disorder

Fig.2: Anatomical lesion mapping of patient group with lobules labeled from the spatially unbiased infratentorial template (SUIT) of the cerebellum and brainstem by Diedrichsen et al.² and being visualized on MRICroN software