

## MRI of Cardiac Function and Apoptosis in Fas Ligand Mouse Model of Dilated Cardiomyopathy and Heart Failure

Patrick Winter<sup>1</sup>, Xiaoyang Qi<sup>2</sup>, Zhengtao Chu<sup>2</sup>, Enkhsaikhan Purevjav<sup>3</sup>, and Jeffrey Towbin<sup>3</sup>

<sup>1</sup>Radiology, Cincinnati Children's Hospital, Cincinnati, OH, United States, <sup>2</sup>Hematology and Oncology, University of Cincinnati, Cincinnati, OH, United States, <sup>3</sup>Heart Institute, Cincinnati Children's Hospital, Cincinnati, OH, United States

**Target Audience:** Basic researchers interested in cardiac functional and molecular MRI.

**Purpose:** The Fas ligand (FasL) is a tumor necrosis factor (TNF) protein that causes cellular apoptosis [1,2]. Apoptosis resulting from FasL expression is also associated with myocardial damage leading to heart failure in humans [3]. Cardiac MRI can noninvasively image the left ventricle throughout the cardiac cycle, allowing accurate measurement of the left ventricular mass and ejection fraction. In dilated cardiomyopathies (DCM), damage to the muscle cells leads to increases in the left ventricular (LV) mass, LV dilation, fibrosis and reduction in the ejection fraction, indicating decreased efficiency in cardiac pumping.

SapC-DOPS vesicles preferentially bind to cells expressing unsaturated, negatively charged phospholipids, such as phosphatidylserine. The outer membrane of apoptotic cells express phosphatidylserine, allowing SapC-DOPS vesicles to selectively image apoptosis [4]. SapC-DOPS vesicles can be formulated with a gadolinium chelate, such as gadolinium-DTPA-bis(stearylamide), for molecular MRI of apoptosis. Improved imaging methods to detect cardiac pathology could advance the treatment of a range of cardiovascular diseases, which are the leading causes of death worldwide.

**Methods:** A transgenic mouse with cardiac-specific overexpression of FasL (Tg-FasL) develops DCM and heart failure due to myocardial apoptosis and fibrotic remodeling [5]. The Tg-FasL mice (n=5) and control non-transgenic littermates (n=3) were anesthetized and imaged with cardiac gating throughout the cardiac cycle in a 7T MRI (Bruker, Ettlingen, Germany). The mice were imaged before and 12 hours post IV injection of Gd-SapC-DOPS vesicles. The short axis cardiac images were processed using segmentation software from Medviso (Lund, Sweden) [6]. The MRI signal intensity of the myocardium was normalized based on the signal from nearby skeletal muscle. Confirmatory histological analysis of the myocardium was performed. Student's two-tailed t-test was used to statistically analyze the resulting data.

**Results:** The Tg-FasL mice showed reduced contraction in the LV compared to non-transgenic mice, leading to obvious pumping deficiency at end systole (**Figure 1**). The LV ejection fraction was lower in Tg-FasL mice compared to control mice ( $46.7 \pm 4.6\%$  vs.  $70.0 \pm 3.7\%$ ,  $p=0.004$ ). The Tg-FasL mice also had LV dilation and increased LV mass ( $74.9 \pm 3.4$  mg vs.  $58.8 \pm 4.2$  mg,  $p=0.01$ ).

After injection of Gd-SapC-DOPS vesicles, the signal intensity of the myocardium increased by  $14 \pm 4\%$  enhancement in the transgenic animals (**Figure 2**). On the other hand, the non-transgenic mice did not show any signal enhancement post injection ( $-2.0 \pm 0.4\%$ ,  $p=0.04$ ). This suggests that the transgenic animals had high levels of myocardial apoptosis while the control animals did not.

**Discussion:** MRI cardiac imaging of Tg-FasL mice shows affected mice have significantly increased LV mass, LV dilation and decreased ejection fraction, consistent with severe DCM. Tg-FasL mice also demonstrate increased signal intensity post injection of contrast agent Gd-SapC-DOPS vesicles, indicating likely apoptosis. These results are important as they increase understanding of cardiovascular pathology in DCM, a leading cause of death in humans. Further studies are in progress to serially track disease progression in this mouse model and corroborate the MRI results with histology.

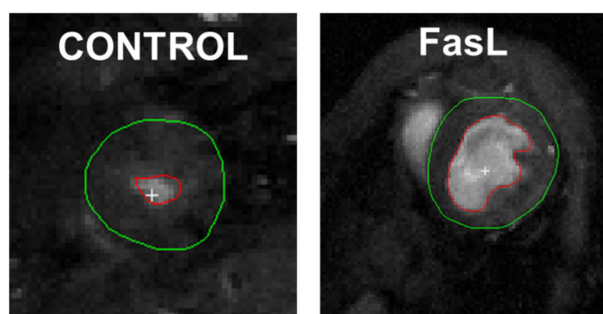


FIGURE 1: Cardiac MRI of the left ventricle at end systole from control (LEFT) and transgenic FasL (RIGHT) mice. The FasL mouse displays clearly abnormal contraction.

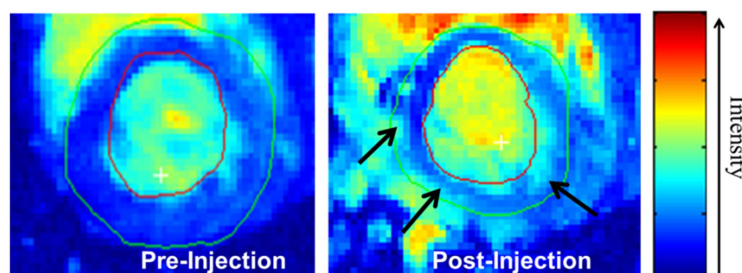


FIGURE 2: MRI of a FasL transgenic mouse post injection of Gd-SapC-DOPS vesicles (RIGHT) shows enhancement of the MRI signal intensity (arrows), indicating myocardial apoptosis.

### References:

- [1] Pinkoski, Green. Fas ligand, death gene. *Cell Death Differ.* 6:1174-81, 1999.
- [2] Nelson, et al. Proinflammatory consequences of transgenic Fas ligand expression in the heart. *J Clin Invest.* 105:1199–1208, 2000.
- [3] Setsuta, et al. Ongoing myocardial damage in chronic heart failure is related to activated tumor necrosis factor and Fas/Fas ligand system. *Circ J.* 68:747-750, 2004.
- [4] Ran, Thorpe. Phosphatidylserine is a marker of tumor vasculature and a potential target for cancer imaging and therapy. *Int J Radiat Oncol Biol Phys.* 54:1479–84, 2002.
- [5] Purevjav, et al. Myocardial Fas ligand expression increases susceptibility to AZT-induced cardiomyopathy. *Cardiovasc Toxicol.* 7:255, 2007.
- [6] Heiberg, et al. Design and validation of Segment – a freely available software for cardiovascular image analysis. *BMC Medical Imaging.* 10:1, 2010.