

Artifacts in the segmentation-based attenuation correction of MR/PET and their impact on PET quantification

Cornelia Brendle¹, Holger Schmidt², Anja Oergel¹, Ilja Bezrukov², Mark Mueller³, Christina Pfannenbergl¹, and Nina Schwenzer¹

¹Radiology, Tuebingen, Baden-Wuerttemberg, Germany, ²Preclinical Imaging, Tuebingen, Baden-Wuerttemberg, Germany, ³Nuclear Medicine, Tuebingen, Baden-Wuerttemberg, Germany

Purpose: PET attenuation correction in hybrid MR/PET systems is routinely performed acquiring a 3D T1-weighted FLASH sequence with Dixon-based fat-water separation and subsequent calculation of a segmentation-based attenuation correction map. The so called mumap differentiates soft tissue, fat, lung and background as approximate attenuation classes. ¹ The mumap is prone to artifacts, which may impair correct lesion quantification in PET. ² Therefore the aim of this study was to analyze artifacts in the attenuation correction map and their impact on PET quantification as well as incorrect tissue classification in PET positive lesions in order to avoid pitfalls in the daily reports in hybrid MR/PET.

Methods: The datasets of 100 patients with different oncological and non-oncological diseases, undergoing clinically indicated PET/CT and subsequent MR/PET examination, were retrospectively searched for areas in general and PET positive lesions with wrong tissue identification in the mumaps. The exact type of tissue misclassification, the artifact volume and the mean standard uptake value (SUV) in the corresponding PET image were assessed and compared with an appropriate control region. The SUV differences were tested for significance using Wilcoxon test, the significance level was set at a p value <0.05.

Results: 276 artifacts were found in total, corresponding to nearly 3 artifacts per MR/PET dataset. The most frequent artifact localizations were the borders of the FOV (n=55), the lungs (n= 39) and the outer body contours (n=31) (see Figure 1). For 106 artifacts an appropriate control region was available in the corresponding PET images. Significant SUV changes were found in certain kinds of tissue misclassification caused by breathing movements at the diaphragm (n=9; SUV 1.10 vs.0.67; p=0.0031), erroneous enlargement of the body contours with skin thickening (n=15; SUV 0.28 vs. 0.11; p=0.0112), at the lung borders (n=8; SUV 1.02 vs. 0.60; p=0.0033), around metal implants (n=23; SUV 0.51 vs. 0.79; p=0.0134) and within the head especially in the brain (n=3; SUV 0.78 vs. 0.47; p=0.0495). Of 184 PET positive lesions in 78 patients, 38 lesions in 15 mumap datasets showed a tissue misclassification. Significant SUV underestimation was found in lesions located in metal artifacts (n=5; SUV 1.60 vs. 6.32; p=0.0090).

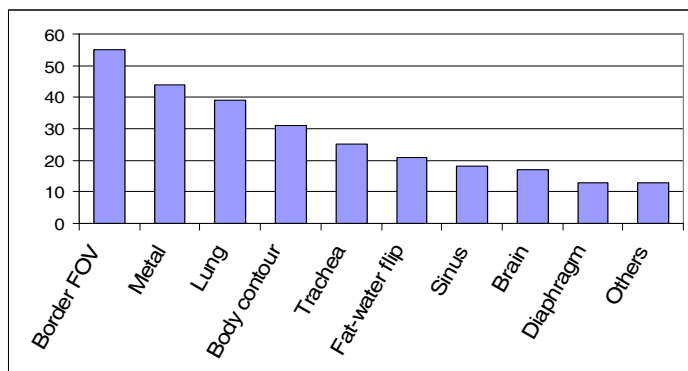


Figure 1: total number of different causes for mumap artifacts

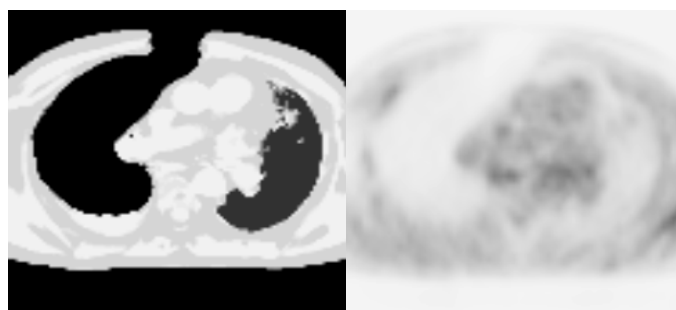


Figure 2: patient example with mumap (left) and corresponding PET (right) of a dataset with a metal artifact caused by sternal cerclages and consecutive misrecognition of the right lung

Discussion: Artifacts in the mumap of routine MR/PET examinations must be expected. Especially in the lungs and the surrounding of metal implants suspect lesions in PET may be found. The sensitivity and specificity of MR/PET in lesion characterization can severely be impaired by mumap artifacts and consecutive SUV changes. Therefore, we recommend checking mumaps for artifacts if lesions in these areas are found in order to avoid false negative or false positive reports in hybrid MR/PET.

References:

[1] Martinez-Moller A, Souvatzoglou M, Delso G, Bundschuh RA, Chefd'hotel C, Ziegler SI, et al. Tissue classification as a potential approach for attenuation correction in whole-body PET/MRI: evaluation with PET/CT data. *Journal of nuclear medicine*. 2009;50(4):520-6.

[2] Keller SH, Holm S, Hansen AE, Sattler B, Andersen F, Klausen TL, et al. Image artifacts from MR-based attenuation correction in clinical, whole-body PET/MRI. *Magma*. 2013;26(1):173-81.