

A REPRODUCIBILITY STUDY OF ARTERIAL SPIN LABELING BASED GLOMERULAR FILTRATION RATE ESTIMATE

BIN CHEN¹, Hao Li¹, Ya Cao¹, Chengyan Wang¹, Xiaoying Wang^{1,2}, JUE ZHANG^{1,3}, and Jing Fang^{1,3}

¹Academy for Advanced Interdisciplinary Studies, Peking University, Beijing, Beijing, China, ²Radiology, Peking University First Hospital, Beijing, Beijing, China, ³College of Engineering, Peking University, Beijing, Beijing, China

Purpose:

Dynamic contrast-enhanced MR imaging (DCE-MRI) has a potential to provide useful quantitative parameters of renal function, however, it relies on the use of gadolinium-based MR contrast agents, which could lead to nephrogenic systemic fibrosis (NSF) [1]. Recently, a noninvasive technique based on arterial spin labeling (ASL) method has been proposed [2,3]. The authors explored a FAIR-ASL sequence with a variable echo time (VTE) to label blood as an endogenous tracer in acquisition. And a two-compartment model was used to extract the blood and urine components signal from the time-course ASL images. In this study, our purpose is to verify the reproducibility of this technique to measure glomerular filtration rate (GFR) in human kidneys.

Materials and Methods :

Six healthy young human subjects (4 men and 2 woman, 22-25 years) participated in this reproducibility study on 3.0T whole body MR scanner (Signa Excite™, GE Medical Systems, Milwaukee, WI, USA) with a TORSOPA coil. The ASL images were acquired using variable TEs ranging from 20 to 120ms with an increment of 20ms. GRE-EPI with FAIR preparation sequence was scanned with the following parameters: TR=800ms, flip angle=90°, slice thickness=5mm, matrix=128 × 128, FOV=260mm. Inversion time (TI) of 1500ms and inversion slice thickness of 20mm were used [4], and four paired tag/control images were acquired in one examination for each TE. All the subjects were required to hold breath for 26 seconds during each examination to avoid respiration motion artifacts. Totally three times of FAIR-ASL scans were conducted: scan1, scan2 and scan3.

The four paired images were averaged to obtain ASL images for each TE and totally six signal points were obtained. Pixels-wise fitting of the time-course signal were calculated by a dual-exponential model to extract extraction fraction maps. The perfusion maps were calculated by a single-compartment model [5], using a home-made program in MATLAB. Then, the GFR map was estimated with the extraction fraction map and perfusion map.

Results:

Fig. 1 illustrates tag images in three repeat scans. The images of renal parenchyma in these repeat studies show high quality and comparable contrast. Typical GFR maps for one healthy subject are shown in Fig. 2. High GFR values are found in cortex and relative low values are found in medulla for all the scans.

In this reproducibility study, each subject is scan for three times, and estimated GFR values of each kidney are presented in Fig. 3 a) for right kidneys and b) for left kidneys. No significant differences are found between repeated scans, $p>0.05$. The average cortical GFR value is 41.29 ± 8.9 ml/100g/min at scan1, 39.63 ± 7.7 ml/100g/min at scan2 and 42.07 ± 6.3 ml/100g/min at scan3 for right kidneys, while the average cortical GFR value of the left kidneys is 36.12 ± 5.0 , 35.42 ± 5.2 and 35.48 ± 8.1 ml/100g/min for each scan, respectively. The corresponding mean values plot of all the subjects in this study is shown in Fig. 4.

Conclusions:

In this reproducibility study, we demonstrated a feasible approach for noninvasive estimation of renal GFR based on ASL technique and verified its reproducibility in human. The proposed method shows robust performance in pixel-wise calculation, which makes it possible to obtain the GFR mapping. In DCE-MRI, measurement of GFR is limited to the use of gadolinium-based MR contrast, which may lead to NSF. However, our ASL-based estimation of GFR is a potential method for assessment of renal status in single kidney. We hope that it could be used in clinic in the future.

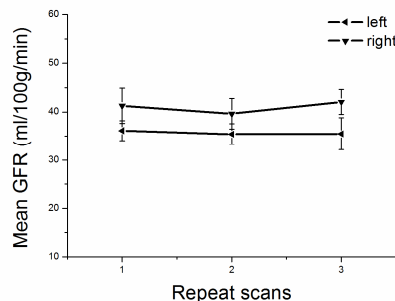


Fig. 4 Mean results of GFR in the reproducibility study. Negligible alterations are found between three repeated scans.

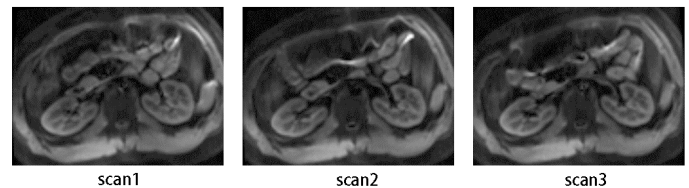


Fig. 1 Tag images for scan1, scan2 and scan3 with TR/TE of 800/20ms.

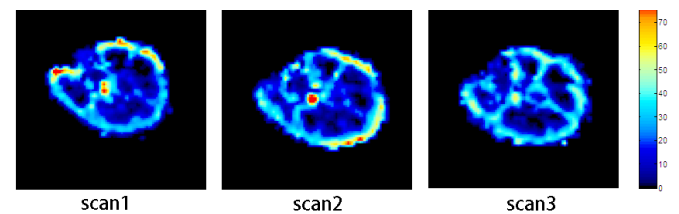


Fig. 2 Typical results of GFR mapping in scan1, scan2 and scan3, respectively. Higher GFR values are found in cortex.

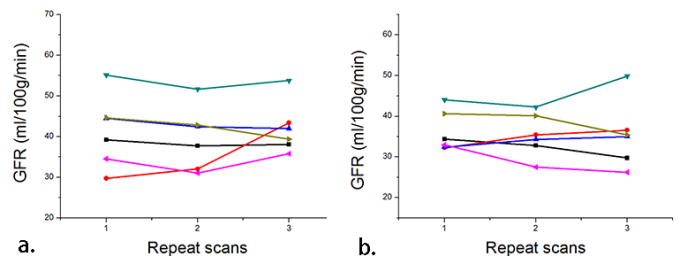


Fig. 3 GFR values of each subject for a) the right kidney and b) the left kidney. Unit of the results is ml/100g/min.

References:

- [1] Grobner T. Nephrol Dial Transplant 2006;21:1104–1108.
- [2] Jing W, et al. Proc. Intl. Soc. Mag. Reson. Med. 20 (2012).
- [3] Jing W, et al. Proc. Intl. Soc. Mag. Reson. Med. 21 (2013).
- [4] Wong, et al. Magn Reson Med 1998;39:702.
- [5] Detre, et al. Magn Reson Med 1992;23:37–45.