

Whole-brain distortion-free pseudo-continuous arterial spin labeling using multiband turbo-FLASH at 3 and 7T

Yi Wang¹, Steen Moeller², An T. Vu², Kamil Ugurbil², Essa Yacoub², and Danny JJ Wang¹

¹Neurology, UCLA, Los Angeles, CA, United States, ²Center of Magnetic Resonance Research, University of Minnesota, MN, United States

Introduction

Multiband (MB) imaging or simultaneous multi-slice (SMS) excitation has recently been applied for arterial spin labeling (ASL) perfusion MRI using Blipped-CAIPI based EPI readout [1, 2]. It has been shown that this technique can expedite ASL imaging acquisition, improve image coverage and/or resolution with little penalty or even gain in SNR. Another advantage of MB acquisition for ASL is shortened T_1 relaxation of the label, which degrades ASL signal in conventional sequential 2D EPI readout. However, MB EPI still suffers from susceptibility, N/2 ghosting and other distortion artifacts, especially at high and ultrahigh magnetic fields. In this work, we present a MB turbo-FLASH (TFL) based pseudo-continuous ASL (pCASL) sequence that is able to provide whole-brain distortion-free perfusion images at both 3 and 7T.

Methods

Six healthy subjects (age=21±3 yrs, 5 female, 1 male) were imaged on Siemens MR scanners at 3 and 7T using 32-channel head coils, three on 3T, three on 7T. To improve the un-aliasing efficiency of MB reconstruction, a FOV/3 or FOV/4 shift along phase encoding was achieved by modulating the phase of the MB excitation pulses using the CAIPRINHA technique [3]. Single band (SB), MB with 3 and 5 simultaneously excited slices were acquired using the following parameters: FOV=220-256mm², matrix=128x128, slice thickness=4-5mm, number of SB slices=3, each slice acquisition took 300ms, distance factor=40%, TR/TE = 3500/2.0ms, flip angle=7°, post labeling delay=1s, label offset = 80-90mm, label duration=1.5s and 60-80 measurements. Parameters at 7T were adjusted slightly due to SAR limitation: measurements=40 with delays between TRs, pCASL labeling duration=1s. For comparison, imaging positions of the central slices of MB acquisitions were kept the same as that of SB acquisition. Images were reconstructed using the slice-GRAPPA algorithm [4]. Quantitative evaluation including temporal SNR (tSNR) and spatial SNR (sSNR) of control and perfusion-weighted images (PWI) were performed for SB, MB3 and MB5 [2].

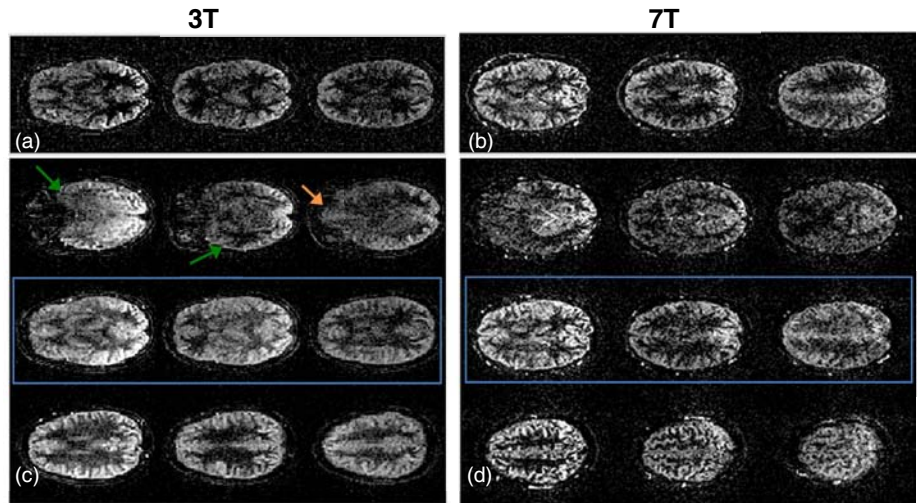


Figure 1. Example PWI acquired using SB (a, b) and MBx3 (c, d) at 3T (a, c) and 7T (b, d). Each column in MBx3 (c, d) represents slices that were acquired simultaneously. The image positions of the central slices (shown in blue rectangles in c, d) of MB3 are identical to that of the SB images.

Results

Example PWIs from SB and MB3 are shown in Fig. 1 at 3T (a, c) and 7T (b, d) respectively. High image quality and comparable visual details can be observed in both SB and MB3 images at the two field strengths. Due to the short TE (2ms) of TFL acquisition, PWI showed no distortion or signal dropout in orbitofrontal (orange arrow) and inferior temporal (green arrow) regions, even at 7T. The absolute tSNR and sSNR of control images were both higher at 7T compared to 3T, however, SNR between PWIs at 3 and 7T are comparable. This is expected given the reduced labeling duration and number of measurements at 7T. Normalized tSNR and sSNR of MB PWI and control images relative to the corresponding measurement using SB acquisition are listed in Table 1. As MB factor increases from 3 to 5, SNR generally decreases for all scenarios. One distinct difference between the two field strengths is that the PWI SNR from the MB images are higher than the SB images at 3T, whereas 7T data show opposite trend; possibly related to differences in implementation but is still being explored.

Table 1. Normalized tSNR and sSNR of MB3, MB5 PWI and control images relative to the corresponding SB images at 3 and 7T

	tSNR at 3T		sSNR at 3T		tSNR at 7T		sSNR at 7T	
	MBx3	MBx5	MBx3	MBx5	MBx3	MBx5	MBx3	MBx5
PWI	1.49±0.47	1.13±0.42	1.66±0.42	1.17±0.40	0.69±0.23	0.65±0.12	0.70±0.09	0.57±0.01
Control	1.06±0.12	1.04±0.15	1.14±0.07	1.05±0.18	0.66±0.14	0.71±0.07	0.65±0.12	0.61±0.01

Conclusion

In this proof-of-concept work, we developed and evaluated a MB TFL based pCASL sequence at 3 and 7T. The feasibility of this technique to provide whole-brain distortion-free perfusion images at high and ultrahigh magnetic fields is demonstrated. MB TFL based pCASL may overcome shortcomings of MB EPI based ASL such as susceptibility related signal dropout and distortion. It also allows seamless co-registration between perfusion and structural MRI acquired using MPAGE. The decreased SNR of MB images relative to SB images at 7T may be related to the delay time inserted between TRs to avoid SAR overflow. Future work includes combining MB acquisition with in-plane parallel imaging to further improve the acceleration, as well as optimizing MB pulses to minimize SAR at 7T.

References:

1. Kim T., et al., MRM, 2013 (E-pub).
2. Feinberg D., et al., MRM 2013. (E-pub)
3. Felix B., et al., MRM 2005; 53:684–91.
4. Setsompop K, et al., MRM, 2012; 67:1210–24.