

## The anisotropic component of diffusion improves visualisation of fiber tracts in the presence of oedema

Lawrence Kenning<sup>1</sup>, Martin Lowry<sup>2</sup>, and Lindsay W Turnbull<sup>2,3</sup>

<sup>1</sup>Centre for Magnetic Resonance Investigations, University of Hull, Hull, East Riding of Yorkshire, United Kingdom, <sup>2</sup>Centre for Magnetic Resonance Investigations, Hull York Medical School at the University of Hull, Hull, East Riding of Yorkshire, United Kingdom, <sup>3</sup>Hull and East Yorkshire Hospitals NHS Trust, East Riding of Yorkshire, United Kingdom

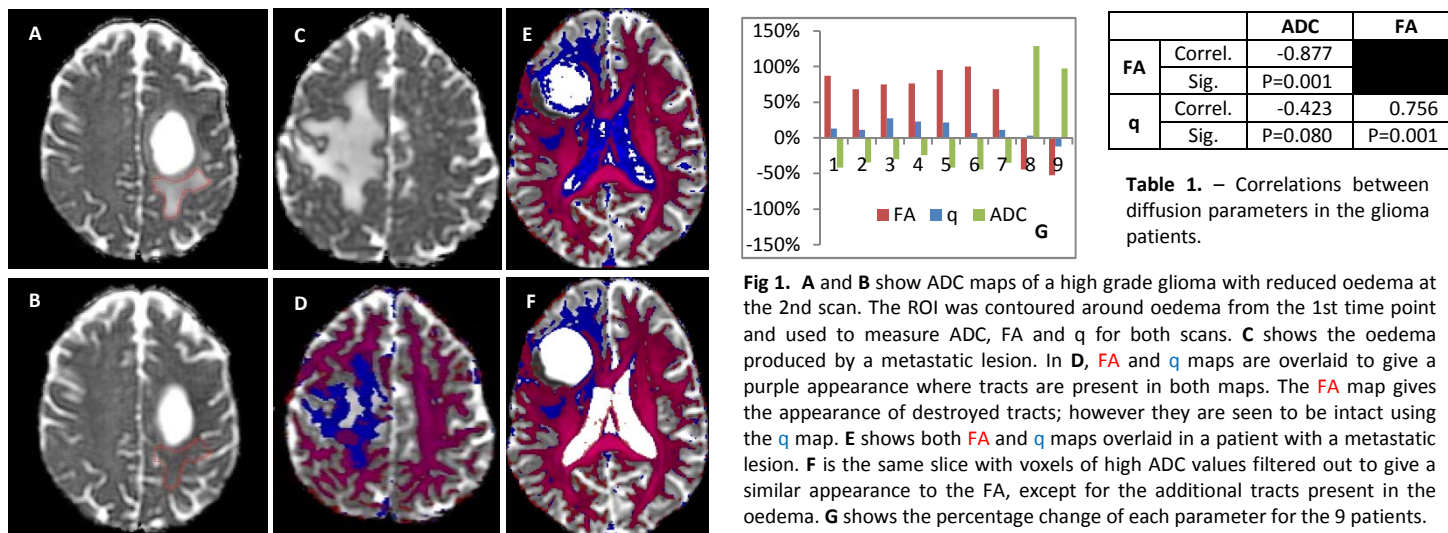
**Introduction:** Diffusion tensor imaging (DTI) can be used to visualise white matter fiber tracts in the brain. Normally this uses the fractional anisotropy (FA) of each voxel. However, demyelination, gliosis, vasogenic oedema and tumour infiltration all cause the fractional anisotropy to decrease<sup>1</sup>, even when fiber tracts still exist. Given the increasing role of DTI in surgery<sup>2,3</sup> for the excision of space occupying lesions, a parameter that improves the visualisation of fiber tracts could improve surgical outcomes for patients. This work investigates whether the anisotropic component of diffusion<sup>4</sup> (q) could be used to better visualise fiber tracts in the presence of oedema in brain tumour patients.

**Methods:** Nine patients with histologically proven gliomas were scanned twice (pre- and post-chemoradiotherapy) using a 3.0T GE 750 Discovery system with an eight channel phased array head coil. One cerebral abscess and three patients with metastatic brain lesions were also scanned preoperatively. Whole brain diffusion tensor imaging (32 directions,  $b=1000\text{mm}^2\text{s}$ , TR/TE=6000/90ms, NEX=2, 128x128 matrix, 3mm slice thickness, no gap, 44 slices) was acquired axially using automated AC-PC positioning software (Ready Brain). Datasets were eddy current corrected using FSL<sup>5</sup> before calculating ADC, q and FA parameter maps using in-house software using the following equations:

$$ADC = \frac{\lambda_1 + \lambda_2 + \lambda_3}{3} \quad q = \sqrt{(\lambda_1 - ADC)^2 + (\lambda_2 - ADC)^2 + (\lambda_3 - ADC)^2} \quad FA = \sqrt{\frac{3}{2}} \sqrt{\frac{(\lambda_1 - ADC)^2 + (\lambda_2 - ADC)^2 + (\lambda_3 - ADC)^2}{\lambda_1 + \lambda_2 + \lambda_3}}$$

FA parameter maps were registered together using a rigid 6 degrees of freedom registration (FLIRT) before applying the transformation matrix to the remaining parameter sets. Seven patients were identified as having regions of interest (ROIs) that had reduced oedema at the second scan (Fig.1 A&B). These ROIs were contoured using ADC maps, before using the same ROI to measure mean FA and q values for the tissue. Two patients were observed to have the reverse effect, with new oedema being present on the second scan.

**Results:** In the 7 glioma patients with reduced oedema, the decreased ADC values resulted in a large percentagewise increase to the FA values. The reverse effect was observed in the two patients with new oedema (Fig.1 G). Changes to the percentagewise values of q were greatly reduced when compared to those of FA, in either direction. In non-infiltrative pathologies such as brain metastases and cerebral abscesses, patients were assessed by overlaying FA maps (red) on top of q maps (blue) and windowed to show the same amount of white fiber tracts in the healthy contralateral side. Visual inspection revealed that fiber tracts could be seen passing through the oedema using q parameter maps that were not seen using FA (Fig.1 D). Unfortunately parameter maps of q also appeared to be more sensitive to flow, with structures such as ventricles being seen to have measureable q values (Fig.1 E). When correlating the measurements (N=18) from the glioma patients, FA values significantly inversely correlated with q and ADC values, however, ADC and q did not significantly correlate (Table 1).



**Fig 1.** A and B show ADC maps of a high grade glioma with reduced oedema at the 2nd scan. The ROI was contoured around oedema from the 1st time point and used to measure ADC, FA and q for both scans. C shows the oedema produced by a metastatic lesion. In D, FA and q maps are overlaid to give a purple appearance where tracts are present in both maps. The FA map gives the appearance of destroyed tracts; however they are seen to be intact using the q map. E shows both FA and q maps overlaid in a patient with a metastatic lesion. F is the same slice with voxels of high ADC values filtered out to give a similar appearance to the FA, except for the additional tracts present in the oedema. G shows the percentage change of each parameter for the 9 patients.

**Discussion:** Percentagewise changes of q following altered levels of oedema were reduced when compared to those of FA. Subsequently q could be used to visualise fiber tracts in pre-operative imaging more effectively than fractional anisotropy as implied by Peña<sup>6</sup>. Increased values of ADC are destructive to FA values given the normalisation process which q does not include. High levels of CSF flow could give the appearance of directionality as seen in the ventricles (Fig.1 E), however, the same effect which removes this from the ventricles as part of the normalisation process when generating the fractional anisotropy, also appears to remove intact fiber tracts in the presence of oedema. An alternative method may be to use q maps filtered using a CSF mask (Fig.1 F). In the cases of brain metastases and abscess, the q maps show fiber tracts are still present in the oedema, despite the fractional anisotropy maps suggesting otherwise (Fig.1 D). FA and q values significantly correlated given they are both sensitive to the direction of diffusion; however, the absence of correlation between ADC and q demonstrates sensitivity to different tissue conditions. In cases where FA values increase and ADC values decrease, q values appear to stay similar, which demonstrates that q is a viable parameter for investigating fiber tract integrity.

**Conclusions:** Anisotropic component of diffusion parameter maps continue to show fiber tract directionality in the presence of large amounts of oedema. Parameter maps of q have the potential to influence surgical management of patients with space occupying lesions.

- References:**
- Jellison *et al.* AM J Neuroradiol. (2004) 25:356-369.
  - Nimsky *et al.* Neurosurgery. (2005) 56(1):130-137.
  - Mastronardi *et al.* Clin Neurosurg. (2008) 55:160-4.
  - Basser *et al.* JMRI. (1996) Series B 111:209-219.
  - Jenkinson *et al.* Medical Image Analysis. (2001) 5:143-156.
  - Peña *et al.* BJR. (2006) 79:101-109