

# Lateralization of Temporal Lobe Epilepsy using Intrinsic Property of Water Diffusion in Fornix Crus

Mohammad-Reza Nazem-Zadeh<sup>1</sup>, Jason Schwalb<sup>2</sup>, Hassan Bagher-Ebadian<sup>3</sup>, Fariborz Mahmoudi<sup>1</sup>, Mohammad-Parsa Hosseini<sup>4</sup>, Hajar Hamidian<sup>1</sup>, Abdelrahman Hassane<sup>1</sup>, Olton Meci<sup>1</sup>, Harrini Vijay<sup>1</sup>, Mohammad Emari<sup>1</sup>, and Hamid Soltanian-Zadeh<sup>1</sup>

<sup>1</sup>Radiology and Research Administration Departments, Henry Ford Hospital, Detroit, MI, United States, <sup>2</sup>Neurosurgery Department, Henry Ford Hospital, Detroit, MI, United States, <sup>3</sup>Neurology Department, Henry Ford Hospital, Detroit, MI, United States, <sup>4</sup>Radiology and Research Administration Departments, Henry Ford Hospital, MI, United States

**Target audience:** Neurosurgeons, neurologists, medical physicists, and other researchers interested in temporal lobe epilepsy.

**Purpose:** Mesial temporal lobe epilepsy (mTLE) is the most frequent type of refractory focal epilepsy. It has been shown that magnetic resonance imaging (MRI) findings such as atrophy on  $T_1$ -weighted and hyperintensity on Fluid Attenuated Inversion Recovery (FLAIR) images of ipsilateral mesial structures such as hippocampus can detect the epileptogenic temporal lobe [1]. Many of the patients, who do not have clear lateralization by preoperative visual inspection who might have been identified by quantitative methods, subsequently undergo implantation of intracranial electrodes to determine which, if either, mesial temporal lobe is epileptogenic. Unfortunately, such implantation carries significant risks of infection, intracranial hemorrhage and elevated intracranial pressure [2]. Therefore, there is a need for improved, simple lateralization methods that optimize selection of surgical candidates and reduce the need for placement of intracranial electrodes for long term monitoring. Diffusion weighted imaging (DWI) has been investigated as a potential imaging modality for the detection of physiological and pathological changes in white and gray matter structures engaged in an epileptic network. Extensive changes have been identified in limbic network at large in cases of mTLE associated with hippocampal sclerosis using DWI such as elevation of ipsilateral hippocampal mean diffusivity (MD) that was accompanied by a disparity in the extent of fractional anisotropy (FA) change in the limbic system. [3, 4]. The fornix is an integral component of limbic circuit. There is evidence that the crus of fornix reflects activity of the mesial temporal structures. Our hypothesis was that the hemispheric asymmetry of FA within the fornix crura could be used to confirm the laterality of mesial temporal epileptogenicity. We compare the lateralization of FA asymmetry in fornix crura with hippocampal  $T_1$  volumetry and FLAIR intensity analysis [5, 6].

**Methods:** Twenty-four TLE patients underwent surgical resection with Engel class I. Fifteen cases had observable mesial temporal sclerosis (MTS) by MRI. Ten cases had pathologically proven MTS (pMTS). Nine of patients underwent extraoperative electrocorticography (ECoG) for lateralization. The side of epileptogenicity is confirmed by postsurgical outcome. Preoperative  $T_1$ -weighted, FLAIR, and DWI images of the patients were acquired on a 3.0T MRI system (Signa, GE, Milwaukee, USA).  $T_1$ -weighted images were acquired using spoiled gradient echo protocol (SPGR) with the imaging parameters: TR/TI/TE=10.4/4.5/300 ms, flip angle=15°, voxel size=0.39mm×0.39mm×2.00 mm. FLAIR images were also acquired with the imaging parameters: TR/TI/TE = 9002/2250/124 ms, flip angle = 90°, voxel size = 0.39mm×0.39mm×3.00 mm. DWI images along with a set of  $b_0$  null images (with b-value = 0  $s/mm^2$ ) were acquired using echo planar imaging at 25 non-collinear diffusion gradient directions with a matrix of 128×128, a voxel size of 1.96×1.96×2.6  $mm^3$ , and a b-value of 1000  $s/mm^2$ . The side of epileptogenicity was blinded during all lateralization processes. MTS was pathologically confirmed as Ammon's horn sclerosis by the pathologists in our institution. DWI images were used to calculate FA (as a measure of fiber and myelin integrity), and PDD (principal diffusion direction; eigenvector corresponding to the largest eigenvalue of the tensor). Using previously described fiber tracking method [7], the left and right fornix crura were segmented. The volumetrics of both left and right hippocampi were established from manually drawn ROIs. Using an affine registration tool (FLIRT; [8])  $T_1$  images and the hippocampal boundaries were coregistered to FLAIR images to acquire the mean and standard deviation of FLAIR intensity within the hippocampi [5, 6]. Then, the hemispheric asymmetry of volumetrics and FLAIR mean × standard deviation in hippocampi and FA values in fornix crura were examined for lateralization of the seizure onset.

**Results:** The crus of fornix was segmented for TLE patients (Fig.1). Out of twenty-four TLE patients, twenty-three cases were lateralized correctly by FA asymmetry in the fornix crura, while only 20 and 19 of them were lateralized correctly by volumetry and FLAIR intensity analysis. For all MTS patients (including pMTS), all three methods lateralized the epileptogenic side correctly. Based on lateralization by FA asymmetry in the fornix crura, eight patients would have avoided ECoG monitoring correctly and undergone the resection of mesial temporal structure directly.

For a single TLE patient without an MRI visible MTS, a wrong temporal lobe would have been resected if the decision was to be made only based on FA asymmetry in fornix crura. However, the neurologists take excessive caution in decision making for the patients with nonlesional MRI. We should mention that three FA measurements in fornix crura seemed to fall within the uncertainty range of an FA value. However, the uncertainty analysis should be performed on all three lateralization methods to determine whether an hemispheric variation detected by any lateralization method is beyond the uncertainty [9].

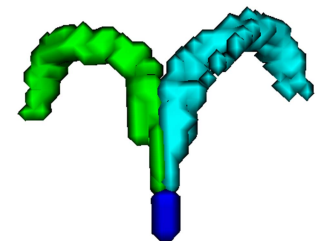
**Conclusion:** Hemispheric asymmetry in individual TLE patients was applied to a proposed potential biomarker, FA of the fornix crura, along with the hippocampal volumetrics and FLAIR mean × standard deviation intensities. These measures could correctly lateralize mTLE in patients who underwent surgery with Engel class I outcomes, even in those for whom extraoperative ECoG was felt to be necessary.

## Acknowledgement:

The authors acknowledge the Foundation for the National Institutes of Health for the financial support of this study (NIH grant R01EB013227).

## References:

[1] Lopez-Acevedo M. L. et al. Swiss Med Wkly 2012; 142. [2] Arya R. et al. Epilepsia 2013. [3] Focke N. K. et al. Neuroimage 2008. [4] Yoo S. Y. et al. American journal of neuroradiology 2002. [5] Akhondi-Asl A. et al. Neuroimage 2011; 54. [6] Jafari-Khouzani K. et al. Neuroimage 2010; 49. [7] Nazem-Zadeh M. R. et al., Medical physics 2012; 39. [8] Jenkinson M. et al. Neuroimage, 2002; 17. [9] Nazem-Zadeh M. R. et al. Phys. Med. Biol., 2013; 58.



**Fig. 1.** A segmented left and right fornix crura