

Segmentation of anterior thalamic nucleus in DTI study: comparison of CSD-based method and conventional DT model

Yi-Hsiu Hsiao¹, Cheng-Yu Chen^{1,2}, Ping-Huei Tsai¹, Hsiao-Wen Chung³, Ming-Chung Chou⁴, Shih-Wei Chiang^{3,5}, Yung-Chieh Chen⁶, and Hung-Wen Kao⁵

¹Department of Medical Imaging and Imaging Research Center, Taipei Medical University Hospital, Taipei Medical University, Taipei, Taiwan, ²Graduate Institute of Clinical Medicine, Taipei Medical University, Taipei, Taiwan, ³Graduate Institute of Biomedical Electrics and Bioinformatics, National Taiwan University, Taipei, Taiwan, ⁴Department of Medical Imaging and Radiological Sciences, Kaohsiung Medical University, Kaohsiung, Taiwan, ⁵Department of Radiology, Tri-Service General Hospital, Taipei, Taiwan, ⁶Department of Biomedical Imaging and Radiological Sciences, National Yang-Ming University, Taipei, Taiwan

Introduction:

The anterior thalamic nucleus (AN) plays an important role in communication among hippocampus, granular retrosplenial cortex and mammillary body. Although the actual mechanism has not been well-known, the AN is thought to contribute to memory processing system in the Papez circuit and to be associated with occurrence of the cognitive impairment [1]. Hence, it is desirable to develop a reliable non-invasive imaging method which is capable of delineating the nucleus. Until recently, several studies have demonstrated that MR diffusion tensor imaging (DTI) could help identify the individual regions of the thalamic nuclei by fiber tracking method [2]. Unfortunately, the derived fiber tracts connecting to the individual thalamic nucleus may not actually reflect the true anatomic location due to insufficient diffusion information and suboptimal reconstruction method. A reasonable solution has recently been proposed using constrained spherical deconvolution (CSD) tractography technique in fiber tracking in vivo [3]. Our aim is to compare CSD-based method with conventional diffusion tensor (DT) model in localization of the AN and the fractional anisotropy.

Materials and Methods:

Eight normal volunteers were enrolled in this study. After conventional MR imaging, diffusion tensor imaging (DTI) sequence was applied on a 3.0T scanner (Discovery MR750; GE Healthcare, Milwaukee, WI, USA) with 8-channel phased-array head coil. The data acquisition parameters were as follows: TR=8000 ms; TE=minimal TE; flip angle=90°; b values=0, 1000 seconds/mm²; diffusion directions=40; FOV=240; matrix size=128×128 (zero-filled to 256×256); section thickness=4 mm; section gap=0 mm; Asset=2; total acquisition time of the DTI sequence=5:36 min. Images were registered first to the B₀ image by using affine registration to minimize the eddy current-induced distortion. After data acquisition, fiber-tracking was performed using either conventional DTI model with deterministic streamlines method and CSD-based technique with probabilistic streamlines method (MRtrix software, Brain Research Institute, Melbourne, Australia). AN was defined using the indirect differentiation method as proposed by Yamada et al. [4] which requires two deterministic seeds for propagation of fibers: One was placed at the mammillary body, and the other was placed at the proximal end of the anterior limb of the internal capsule. The intersected area in the thalamus by the derived tracking fibers was defined as the region of AN as shown in Fig. 1.

Results:

Fiber tracts derived from conventional DT model (green) and CSD tractography method (red) were displayed in a sagittal image as shown Fig. 1a, respectively, and three contiguous transversal slices were determined subsequently for the delineation of the AN (Fig. 1 b-d). Although the ascending fibers were expected to go through the AN along the mamillothalamic tract perpendicularly, the derived fibers from conventional DTI model crossed the level of the AN with an oblique direction resulting in missed identification of the AN (green). In contrast, better consistence was shown in ROIs using CSD method (red). As to quantitative measurements of fractional anisotropy in the AN, significant decrease of the error (from 11.99% to 4.83% error) was observed using CSD method.

Discussion:

Our results showed the advantage of improved localization of AN with the use of CSD-based tractography. This method can consistently produce the expected paths of the mamillothalamic tract and its continuous propagation to cingulate cortex. In addition, quantification of FA in AN region appeared to be more stable with CSD method as compared to DT model (Table 1). In conclusion, our study demonstrated the superiority of CSD-based tractography model in delineation of anatomic location of the AN which help to improve measurement of the FA. This is important for future investigation of the thalamic nuclei.

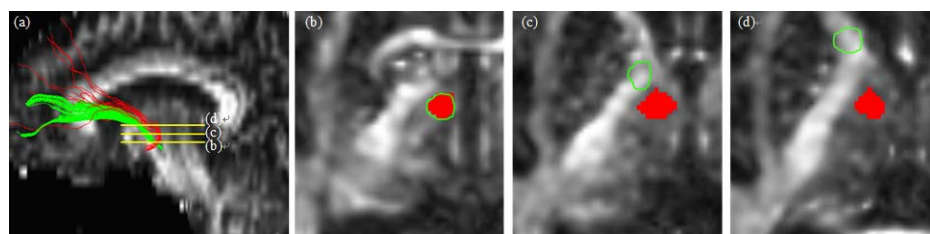


Figure 1 Demonstration of fiber tracts using DT-based (green) and CSD-based (red) tractography (a) and the derived location of the AN in three contiguous axial slices (b-d). The location of AN is erroneously displaced to the internal capsule with DT-based method.

	DT model	CSD method
slice (b)	0.320 ± 0.038	0.320 ± 0.038
slice (c)		0.294 ± 0.021
slice (d)		0.307 ± 0.027
avg.	0.320 ± 0.038	0.306 ± 0.015
err.	11.99%	4.83%

Table 1 Comparison results of FA measurements using DT model and CSD method.

Reference:

- [1] Jang SH, et al. Brain imaging and Behavior 2003;7:236-41
- [2] Wiegell MR, et al. NeuroImage 2003;19:391-401
- [3] Farquharson S, et al. J Neurosurg. 2013;118(5):1367-77
- [4] Yamada K, et al. AJNR Am J Neuroradiol. 2010;31(4):732-5