

Initial Evaluation of the Utility of Ferumoxytol for MR Runoffs

Thomas Hope¹, Rizwan Aslam¹, Judy Yee¹, Anait Sesi¹, Joseph Rapp¹, Christopher Owens¹, and David Saloner¹
¹Department of Radiology, UCSF/SFVA, San Francisco, CA, United States

TARGET AUDIENCE: Researchers and clinicians who have the goal of adequately performing MR runoffs in patients with significant renal disease who cannot tolerate gadolinium based contrast agents (GBCAs).

PURPOSE: MR is commonly used to evaluate for flow limiting stenosis in the lower extremities. Typically these studies are performed with the administration of a GBCA, which are contraindicated in patients with an eGFR < 30 mL/min due to nephrogenic systemic fibrosis. Unfortunately vasculopathies, frequently have significant kidney disease. Ferumoxytol is a FDA approved iron containing compound used clinically for IV iron replacement therapy, typically in dialysis patients. This agent acts as a blood pool USPIO (ultrasmall superparamagnetic iron oxide) particle, with both T1 and T2 shortening properties. We propose to utilize Ferumoxytol for MR runoffs in patients with significant renal disease (*offlabel use*).

METHODS: We performed a MR runoff in six patients, average age of 70 years. The studies were performed on a 3.0T Skyra magnet (Siemens Healthcare). Ferumoxytol (Feraheme, AMAG, Lexington, MA) was diluted one vial of ferumoxytol (12 mLs containing 360 mg of elemental iron) in saline to make a total volume of 60 mLs. We used 1-2 mL timing boluses in the feet and in the abdominal aorta. Subsequently a dynamic TRICKS (Time Resolved Imaging of Contrast Kinetics) sequence was acquired in the feet during a small bolus administration, followed by a multi-bed dynamic acquisition through the abdomen, pelvis, thighs and calves during the administration of the remaining contrast. This acquisition had the following parameters: TR/TE = 3.43/1.12, flip angle = 25, slice thickness = 1.9 mm, and matrix size = 384/269. This was followed by a high resolution acquisition at the same table positions in the steady state of contrast enhancement using the following parameters: TR/TE = 4.27/1.55, flip angle = 25, slice thickness = 0.75, matrix = 640/560.

RESULTS: Ferumoxytol performed well as a blood pool contrast agent for MR runoffs. Incorporating dynamic acquisitions with a lower spatial resolution and higher "steady state" images while the contrast agent is evenly distributed throughout the blood pool allowed for adequate depiction of vascular anomalies. Figure 1 demonstrates an example acquisition from the dynamic phase. Steady state higher resolution images provided increased vascular detail (Figure 2).

DISCUSSION: GBCAs are limited in patients with low renal function. Ferumoxytol is ideal in this population, and in particular it is optimal for vascular imaging as it remains in the vascular blood pool for days with minimal agent within the interstitium. Dilution of the contrast is required to limit T2* effects on the T1 enhancement during the dynamic arterial bolus. While some USPIO formulations can only be infused slowly, the Ferumoxytol injectate can be injected at the same rates as used in conventional Gd studies.

CONCLUSION: Ferumoxytol functions well for MR runoffs in patients with low renal function.

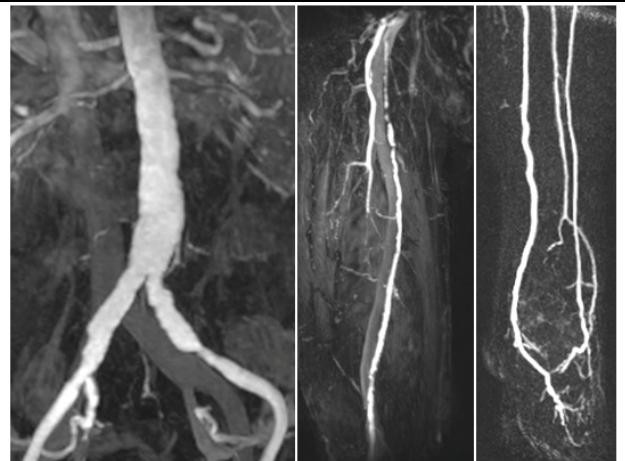


Figure 1: Dynamic low resolution MIPs through the abdominal aorta (left), superficial femoral artery (SFA) (middle), and MIP from TRICKS in the foot (right).

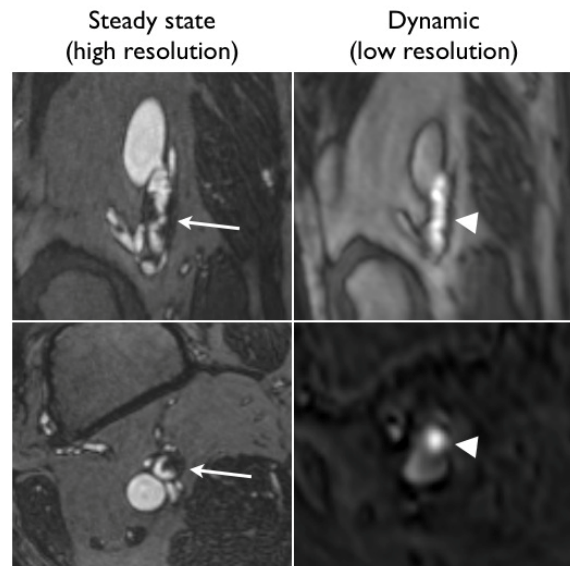


Figure 2: Comparison of high resolution steady state image (right) to dynamic acquisition with low resolution (left) of a focal stenosis in the distal SFA.