

Evaluation of mitral inflow in a rat model of aortic stenosis using phase contrast MRI

Kristine Skårdal^{1,2}, Emil K. S. Espe^{1,2}, Magnus Aronsen^{1,2}, Lili Zhang^{1,2}, and Ivar Sjaastad^{1,2}

¹Institute for Experimental Medical Research, Oslo University Hospital and University of Oslo, Oslo, Oslo, Norway, ²KG Jebsen Cardiac Research Center and Center for Heart Failure Research, University of Oslo, Oslo, Oslo, Norway

TARGET AUDIENCE: Scientists in experimental cardiovascular research

PURPOSE: About 50% of the patients with heart failure have diastolic dysfunction and preserved ejection fraction. Preclinical research is conducted to study the mechanisms behind and progression of diastolic dysfunction in heart failure. An important aspect in assessment of diastolic function involves evaluation of mitral inflow, typically obtained with Doppler echocardiography. However, especially in small animals, methodological limitations with echocardiography, specifically the angle dependency of flow measurements, can be problematic. Phase contrast MRI (PC-MRI) has the potential to provide measurement of 3D blood flow through the mitral valve, assessing mitral filling characteristics and calculating blood volume fluxes. For the first time, we have used PC-MRI to specifically evaluate mitral inflow characteristics in a rat model of cardiac disease.

METHODS: Aortic banding (AB) is a surgical model of human aortic stenosis, causing ventricular remodeling following the increase in afterload, resulting in concentric hypertrophy and progression into heart failure. 6 weeks following surgery, male Wistar rats underwent PC-MRI at the level of the mitral valve. A 3D velocity encoded PC-MRI sequence optimized for blood flow assessment, TR = 2.8 ms, TE = 2.1 ms, Venc = 139 cm/s, FOV = 50 mm × 50 mm, matrix 96 × 96, slice thickness 1.5 mm and flip angle 7°, was applied on a 9.4 T/210 mm/ASR horizontal bore magnet (Agilent Technologies Inc., USA). The PC-MRI data was processed using the method of Bollache et al¹. In short, the method segments the mitral valve orifice throughout diastole by combining detection of flow direction with the largest connected area in the region of the mitral valve in an automatic fashion, allowing extraction of peak flow velocity and deceleration. Additionally, by pixel-wise multiplication of the through-plane velocity component with the segmented mask at each time point, flow rate can be obtained and in turn flow-derived stroke volume (SV) through temporal integration. Flow-derived SV served as an individual reference, and was compared with SV from multislice short axis cine MRI. All measurements are shown as mean ± standard error of the mean.

	Sham (n = 7)	AB (n = 7)
Body weight [g]	367.4 ± 6.6	364.1 ± 8.5
Stroke volume [μL]	364.1 ± 10.1	330.2 ± 14.5
Ejection fraction [%]	70.2 ± 1.1	72.2 ± 1.8
Heart weight [mg]	1083 ± 70	1655 ± 63*
Lung weight [mg]	1437 ± 80	1717 ± 68*

Table 1 Characteristics of sham and hypertrophic banded (AB) animals. * indicate p < 0.05 compared to sham.

RESULTS: The AB animals showed increased heart and lung weight compared to shams, but preserved systolic function (Table 1). Peak mitral flow rate and mitral deceleration rate was significantly increased in AB animals compared to sham (Figure 1A), meaning an increased and sharper filling in AB rats. Bland Altman analysis between SV measurements showed a slight bias of larger SV from cine MRI, mean bias 43.9 μL, limits of agreement: 4.0–83.9 μL. However, this discrepancy between the two methods was not different between the disease groups (Figure 1B).

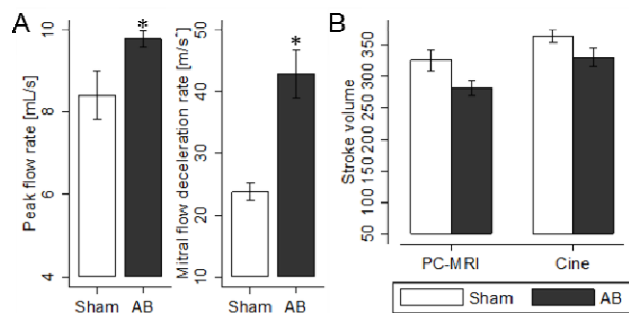


Figure 1 Peak flow rate and mitral deceleration rate was significantly increased in AB rats compared to sham (A). A difference in stroke volume estimate was observed between PC-MRI and cine, while there was no observed disease bias (B). * indicate p < 0.05 compared to sham.

DISCUSSION: For the first time, we have used PC-MRI to detect altered mitral inflow in a rat model. The method showed increasing flow and mitral deceleration rate in the banded rats, as is expected in this model. A small increase in SV was observed with cine MRI compared to PC-MRI; potentially a result of partial volume effects during segmentation of cine, papillary muscles that were included in the lumen of the cine segmentation and/or a systematic underestimation of the diastolic phase from the automatic method, underestimating flow at early or end diastole. Despite this, an important finding is the maintained difference in SV between AB and sham, indicating sufficient temporal resolution of the PC-MRI method to detect peak flow, also in diseased animals.

CONCLUSIONS: PC-MRI can detect alterations in mitral filling in rats with aortic banding; demonstrating how PC-MRI can be a valuable tool in assessment of diastolic dysfunction in basic research. Future work involves detection of flow in conjunction with myocardial velocimetry², allowing assessment of E/e' in rodent models of diastolic dysfunction using PC-MRI.

REFERENCES:

- Bollache E, Redheuil A, Clément-Guinaudeau S, et al. Automated left ventricular diastolic function evaluation from phase-contrast cardiovascular magnetic resonance and comparison with Doppler echocardiography. *J Cardiovasc Magn Reson* 2010;12(1):63.
- Espe EK, Aronsen JM, Skårdal K, et al. Novel insight into the detailed myocardial motion and deformation of the rodent heart using high-resolution phase contrast cardiovascular magnetic resonance. *J Cardiovasc Magn Reson* 2013;15(1):82.