

# Comparison of distributed parameter and Fermi modelling of cardiac MR perfusion with CT perfusion in coronary artery disease versus invasive coronary angiography

Giorgos Papanastasiou<sup>1,2</sup>, Michelle Williams<sup>2</sup>, Mark Dweck<sup>2</sup>, Saeed Mirsadraee<sup>1</sup>, Nick Weir<sup>3</sup>, Shirjel Alam<sup>2</sup>, Colin Stirrat<sup>2</sup>, David Newby<sup>1,2</sup>, and Scott Semple<sup>1,2</sup>  
<sup>1</sup>Clinical Research Imaging Center, University of Edinburgh, Edinburgh, Lothian, United Kingdom, <sup>2</sup>Centre for Cardiovascular Science, University of Edinburgh, Edinburgh, Lothian, United Kingdom, <sup>3</sup>NHS Medical Physics, University of Edinburgh, Edinburgh, Lothian, United Kingdom

## INTRODUCTION

Absolute quantification of myocardial blood flow (MBF) from dynamic contrast enhanced magnetic resonance imaging (DCE-MRI) data through model constrained deconvolution modeling has been shown to lead to a better understanding of coronary physiology and can potentially improve diagnosis and prognostication of coronary artery disease (CAD) <sup>1</sup>. Fermi modeling is well established in cardiac first-pass DCE-MRI data for MBF quantification <sup>1</sup>. Distributed parameter (DP) modeling applied recently in cardiac DCE-MRI estimated accurate values of MBF whilst providing additional information of coronary vascularity and permeability <sup>2</sup>. Recent advances in multidetector-computed tomography (MDCT) have enhanced its role beyond the assessment of coronary stenosis <sup>3</sup>. Transmural perfusion ratio (TPR) calculated from adenosine stress CT perfusion images combined with CT angiography (CTA) can accurately detect stenosis and perfusion abnormalities <sup>3</sup>. DCE-MRI is challenged by the presence of motion and susceptibility artifacts and therefore, absolute quantification of MBF needs further validation. MDCT is currently limited to static perfusion acquisition at the peak of contrast enhancement to minimize radiation exposure <sup>3</sup>. Static perfusion of both resting and hyperemic myocardium is challenging due to heart rate variability and thus, TPR needs further validation. We performed a multimodality perfusion assessment in patients with CAD. We assessed DP and Fermi MBF values versus invasive coronary angiography (ICA) results <sup>3</sup>. We evaluated whether DP or Fermi can more reliably detect hypoperfused areas compared to TPR and CTA.

## METHODS

After informed consent, MR and CT stress-rest perfusion imaging were acquired in 35 patients with CAD. Results are presented here for 5 subjects. DP and Fermi MBF values are compared against ICA, CTP and CTA classification. MR perfusion images were acquired in three short axis views (basal, mid-ventricular, apical) using an established stress-rest DCE-MRI 3T protocol (MAGNETOM Verio, Siemens AG Healthcare Sector, Erlangen, Germany) and 0.05 mmol/kg gadolinium (Gd) (Gadovist, Bayer Healthcare). Left ventricle myocardial segments were contoured using validated software (Medis, Netherlands). DP and Fermi modeling of myocardial Gd concentration curves were performed in Matlab (Mathworks, USA). Myocardial signal intensity curves were converted to Gd concentration curves by adapting the MR signal equation <sup>4</sup>. A prototype modified Look-Locker Inversion Recovery (MOLLI) method <sup>5</sup> was used to quantify T<sub>1</sub> of the myocardium. CT perfusion imaging was performed with a 320-multidetector CT scanner (Aquilion One, Toshiba Medical Systems, Japan) using iodine contrast enhancement (Iomeron 400, Bracco). Tube voltage was selected based on body mass index (BMI) and tube current was selected automatically based on scout image attenuation. Prospective ECG-gated images were acquired at end diastole during rest and adenosine stress (140 mcg/kg/min). A 4 min post adenosine stress protocol was used for both MRI and CT perfusion imaging. CTA and TPR were quantified by 2 blinded observers using Vitrea Fx (Vital images, USA) <sup>3</sup>. ICA stenoses were reported for left anterior descending (LAD), left circumflex (LCX) and right coronary artery (RCA) by an experienced physician.

## RESULTS

We successfully fitted for the first time a 2-region, 1-barrier DP model in data of patients with CAD <sup>2</sup>. 15 vessel territories were examined in total using ICA and 12 obstructive (>70% luminal stenosis) and non-obstructive stenoses were identified in various territories of the three main coronary arteries. DP and Fermi identified severe hypoperfusion (i.e. stress MBF <2 ml/min/ml) in 12 and 9 of these stenotic vessels respectively. DP and Fermi models were more reliable in detecting hypoperfused patterns compared to TPR which correctly identified abnormal patterns in only 5 stenotic vessels (abnormal CTP<1) <sup>3</sup>. CTA detected pathophysiological stenosis in 11 stenotic vessels whilst identifying non-obstructive stenosis in 1 normal vessel. Figure 1 shows mean DP- (c) and Fermi-MBF (d) values versus CTA classification (1=normal, 2=non-obstructive, 3=obstructive) which possibly suggests that DP is more reliable in detecting lower perfusion due to increases in luminal stenosis than Fermi. Mean DP- and Fermi-MBF at stress were lower (2.50±0.61 and 2.46±1.06 ml/min/ml respectively) in normal vessels (group 1, CTA classification) compared to relative mean DP and Fermi values in 8 healthy volunteers (3.16±0.71 and 3.57±0.60 ml/min/ml respectively). A t-test did not demonstrate significant differences between MBF values for this small cohort. Further validation is underway in our larger patient cohort.

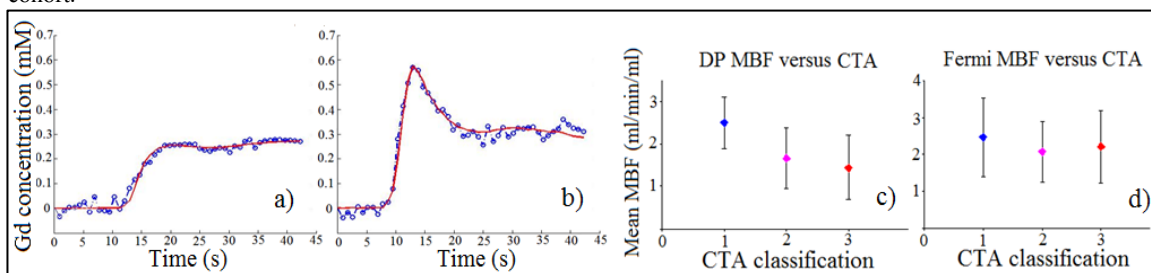


Figure 1) DP model (red) in a) pathological and b) normal myocardial segment. Mean stress c) DP- and d) Fermi-MBF values versus CTA classification.

## DISCUSSION

DP successfully fitted cardiac MR data of patients with CAD. MR perfusion modeling using Fermi and DP was more reliable in detecting severely abnormal perfusion territories than TPR from static CTP data. DP model was more precise in detecting lower perfusion areas as a function of luminal stenosis increases than Fermi versus CTA classification. DP was capable to detect hypoperfusion in all stenotic vessels versus ICA findings. DP- and Fermi-MBF was lower in group 1 of CTA classification compared to healthy subjects. These results may suggest that coronary hemodynamics can be influenced in areas not readily identified by ICA due to decreased cardiac function in patients with CAD.

## REFERENCES

1. Jerosch-Herold, M. Journal of Cardiovascular Magnetic Resonance, 2010, 12:57
2. Broadbent et al. Magnetic Resonance in Medicine, 2013,00:000-000.
3. George, R.T. et al. Circulation: Cardiovascular Imaging, 2009, 2(3):174-182.
4. Larsson, H. B. W. et al. Magnetic Resonance Medicine, 1996, 35:716-726
5. Messroghli, D.R. et al. Magnetic Resonance in Medicine, 2004, 52(1):141-146