

## Novel intervention for acute migraine headache investigated by BOLD fMRI

Tie-Qiang Li<sup>1</sup>, Yanlu Wang<sup>1</sup>, Rolf Hallin<sup>2</sup>, and Jan-Erik Juto<sup>3</sup>

<sup>1</sup>Department of Medical Physics, Karolinska University Hospital, Huddinge, Stockholm, Sweden, <sup>2</sup>Department of Neurophysiology, Karolinska University Hospital, Huddinge, Stockholm, Sweden, <sup>3</sup>Department of CLINTEC, Karolinska Institute, Huddinge, Stockholm, Sweden

**TARGET AUDIENCE:** Clinicians who are interested in novel interventions for neurological disorders, neuroscientists who are interested in the interplay between the status of autonomic nervous system (ANS) and central nervous system (CNS) disorders and MRI physicists who are interested in fMRI study of neurological interventions.

**PURPOSE:** Hypothalamus is the control center of ANS which innervates cardiac and smooth muscles, various endocrine and exocrine glands; it influences the activity of most tissues and organ systems in the body. Therefore, Hypothalamus plays a critical role in maintaining homeostasis in the human body. ANS dysregulation is of significant clinical importance in terms of behavioral symptoms and designing therapeutic intervention. The purpose of this study is to investigate the dynamical functional response in hypothalamus to a novel therapeutic intervention which has been shown to be extraordinarily effective for treating migraine headache and understand the underlying neurological mechanisms for the intervention.

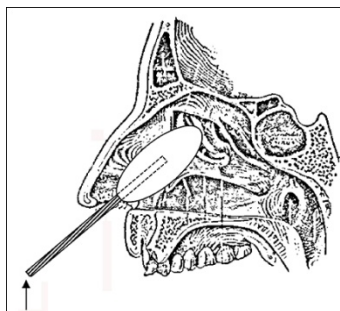
**METHODS:** The innovation and its applications for treating different disorders have been described in multiple patent filings, e.g., US 2010/0274164 A1, US 2013/0158448 AL and etc. In brief, the treatment is aimed at normalizing ANS function by delivering low frequency vibration stimulation into the posterior part of the nasal cavity mucosa and its nerve endings (Fig. 1). Among other tests, the intervention has been tested on a group of 40 migraine patients showing very promising long standing results. All these patients were relieved from their pain or aura during treatment. Over 70% of the treated patients have so far experienced a prolonged headache free period up to 6 months, as followed up by telephone interviews. The present study involved the treatment of 9 normal controls (female/male=8/1) and 9 migraine patients (female/male=8/1) during migraine headache attack inside a whole-body clinical 3T MRI scanner (Trio, Siemens) with simultaneous resting-state fMRI measurements. The imaging protocol consisted of multiple sessions of whole-brain BOLD fMRI scans each lasted 10 min. The main acquisition parameters included the following: TE/TR=35/2000ms, spatial resolution of 3.5 mm, single-shot BOLD EPI with IPAT factor=2, and 300 timeframes. When the patients arrived, the migraine headaches were on-going. Before the treatment, the patients were asked to perform two sessions of control scans: a baseline without probe and a session without treatment but with inserted treatment probe, followed by one or two sessions of treatment inside the MRI scanner with continuous BOLD fMRI recordings. After each session the patients were asked to evaluate their pain level. All patients studied were totally pain relieved after 10-20 minutes of treatment. At the end, a control session of resting-state without the inserted treatment probe was performed. Since the treatment is non-invasive and involves no-chemical agent, we applied also the same intervention and fMRI protocol to the normal controls. The fMRI data were first pre-processed with a pipeline procedure<sup>1</sup>, based on AFNI including mainly motion correction, baseline detrending, low-pass filtering at 0.1Hz and registration to standard MNI template, then group ICA were performed using the GIFT package<sup>2</sup>. The ICA results were statistically assessed using a 3-way ANOVA model with group and treatment as fixed effects and subjects as random effect.

**RESULTS:** With the group t-test maps from ICA we identified 22 independent components (ICs) as meaningful resting-state functional networks (RFNs) by visual inspection and comparison to literature reference results<sup>3</sup>. Most of the RFNs are consistent with those reported from resting-state fMRI studies of healthy volunteers except for two networks involving hypothalamus and thalamus, respectively. Further analysis of these ICs from individual subjects with 3-way ANOVA indicates that there is significant treatment effect involving the IC component associated with hypothalamus (Fig. 2).

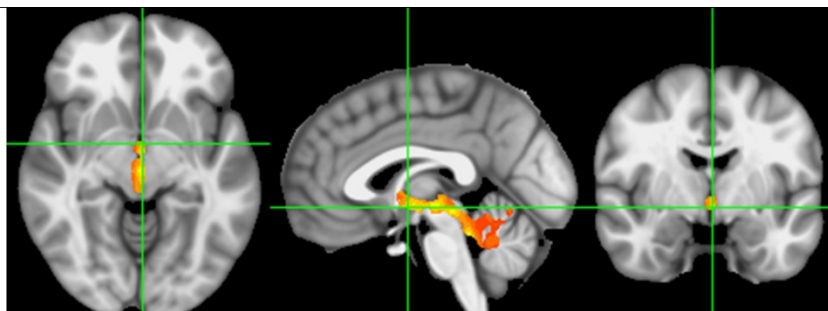**DISCUSSION:** In terms of homeostasis in the hypothalamic area, migraine is of special interest to study. Migraine patients have a normally regulated ANS when symptom free between attacks. However, during headache attacks they often suffer the symptoms of an unbalanced ANS. Growing evidence from functional imaging studies<sup>4</sup>, such as the current study, indicates that the basal part of the CNS and particularly hypothalamus plays a very important role in the pathogenesis of migraine attacks. Further detailed elucidation of involved functional networks is currently limited by the available spatial resolution of the used fMRI techniques at 3T. In order to identify the hierarchy of the functional networks associated with the hypothalamic area and study how the treatment affects the interplay between the involved ANS and CNS networks, fMRI data with sub-millimetre resolution are required.

**CONCLUSION:** The intervention has very positive impact on the normal functioning of ANS possibly by restoring homeostasis in the basal parts of the brain and the hypothalamic area. The resting-state BOLD signal change under different interventional conditions indicate that restoring the physiological homeostasis in hypothalamus and associated functional network at the basal of the brain provides an efficient approach for the treatment of central nervous system disorders such as migraine. Better understanding of the hierarchy of functional connectivity networks associated with the hypothalamic area and how this cost-effective intervention affects the interplays between the involved networks can further optimize and extend the treatment to other neurological diseases by taking advantage of the interplay between ANS status and CNS disorders.

**REFERENCES:** 1) Li X., Li T. Q., Andreasen N., et al. *Sci Rep* 3:1339, (2013). 2) Wang Y. and Li T.Q. *Plos One* 8:e76315 (2013). 3) Allen E.A, Erhardt E.B, Damaraju E. et al., *Front Syst Neurosci.* 5:2 (2011). 4) Kato Y, Araki N, Matsuda H, et al. *J Headache Pain*, 11:255 (2010).



**Fig. 1.** Schematics of the intervention with inserted probe into the nasal cavity.



**Fig. 2.** Brain network associated with hypothalamus showing significant treatment effect of the intervention as assessed with a 3-way ANOVA model at  $p < 0.05$  and cluster size of 40 voxels.