

Comparison of T1, T2 and PDFF measured by ¹H MR spectroscopy with histologic fibrosis stage.

Gavin Hamilton¹, Michael S Middleton¹, Tanya Wolfson², Anthony C Gamst², Jonathan C Hooker¹, William M Haufe¹, Brandon D Ang³, Rohit Loomba³, and Claude B Sirlin¹

¹Department of Radiology, UC San Diego, San Diego, California, United States, ²Computational and Applied Statistics Laboratory, SDSC, UC San Diego, San Diego, California, United States, ³Department of Medicine, UC San Diego, San Diego, California, United States

Target Audience: The abstract is aimed at radiologists and physicists with an interest in non-alcoholic steatohepatitis (NASH).

Introduction: We have developed a rapid multi-TR, multi-TE ¹H MRS sequence for *in vivo* hepatic fat quantification and characterization that acquires 32 single-average spectra in a single breath-hold (**Table 1**), allowing collection of liver proton density fat fraction (PDFF), and water and fat T1 and T2 values as part of a standard clinical MR exam. Here we compare measured MRS parameters with histologic fibrosis stage to see if any MR parameters assist in the non-invasive assessment of NASH.

Methods: Acquisition: *In vivo* ¹H MR spectra were acquired without contrast at 3 Tesla (GE Signa EXCITE HDxt, GE Healthcare, Waukesha, WI) using an 8-channel torso array coil in 55 adult subjects with suspected or previously diagnosed NASH, who also were undergoing a clinical liver biopsy. A 20 x 20 x 20 mm voxel was selected within the liver, avoiding liver edges and major blood vessels. Thirty-two spectra (including four preparatory acquisitions) were acquired in a 21 s breath-hold using a modified Stimulated Echo Acquisition Mode (STEAM) sequence (timings in **Table 1**). A minimum mixing time (5 ms) was used to reduce j-coupling effects. Bandwidth was 5000 Hz, and 256 data points per spectrum were acquired with no water or spatial saturation. The selected voxel was shimmed during free breathing. Liver biopsy was acquired within 90 days MR exams. No attempt was made co-locate the MRS voxel and biopsy site.

Table 1: Sequence timing of the multi TR-TE sequence. P1-P4 are pre-pulse excitations. Scan time 20.95 s.

Spect No.	P1	P2	P3	P4	1	2	3	4	5	6	7	8	9	10	11	12
TR (ms)	150	150	150	150	150	225	300	400	600	900	2000	1500	700	450	325	250
TE (ms)	10	10	10	10	10	10	10	10	10	10	10	10	10	10	10	10
Spect No.	13	14	15	16	17	18	19	20	21	22	23	24	25	26	27	28
TR (ms)	175	200	275	350	500	800	1250	1000	1000	1000	1000	1000	1000	1000	1000	1000
TE (ms)	10	10	10	10	10	10	10	10	15	20	25	30	50	70	90	110

Analysis: Spectra from the individual channels were combined using singular value decomposition (1). A single experienced observer analyzed the spectra using the AMARES algorithm (2) included in the MRUI software package (3). The results were analyzed with a custom Matlab routine that non linearly fitted the measured peaks area to the standard equation $S = S_0(1 - \exp(-\frac{TR}{T_1})) \cdot \exp(-\frac{TE}{T_2})$. T1 and T2 were calculated for 'water' (4-6 ppm) and fat (0-3 ppm) as well as the individual fat spectral peaks; PDFF was corrected for fat included in the 'water' peak from a previously-established standard liver spectrum (4). Histologic liver biopsy slides were scored by a hepatopathologist using the NASH CRN histologic scoring system. NASH was diagnosed if histologic findings were borderline or definitive for steatohepatitis. Wilcoxon tests were used to see if a significant difference could be distinguished between subjects with and without NASH, subjects without (stage 0) and with fibrosis (stages 1-4), and subjects with advanced fibrosis (stage ≥ 3 i.e., bridging fibrosis or cirrhosis) with those with lesser or no fibrosis (stages 0-2).

Results: Typical T1 and T2 recovery curves for fat and water are shown in **Figures 1** and **2**. The results are shown in **Table 2**. None of the MRS parameters measured were significant for distinguishing non-NASH from NASH. For fibrosis the most significant difference was seen in water T2 which showed significant differences in both subset comparisons.

Discussion: There were significant differences in water T2 with fibrosis, with higher values being associated with advanced fibrosis. The mechanism for change in T2 with fibrosis requires further study. However, the study was limited by the small number of subjects with advanced fibrosis, and further studies with larger numbers of subjects are required.

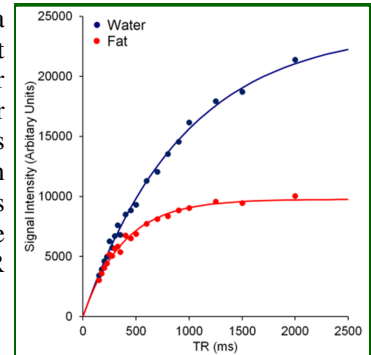


Figure 1: Typical T1 recovery curves for water and fat

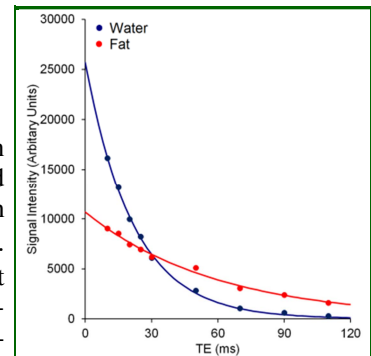


Figure 2: Typical T2 recovery curves for water and fat.

	n	PDFF	Water		Fat (0-3 ppm)	
			T1	T2	T1	T2
Non NASH	9	17%	917 ms	21.3 ms	351 ms	57.6 ms
NASH (probable or definite)	46	15%	919 ms	23.8 ms	361 ms	57.4 ms
p-value	-	0.65	0.94	0.14	0.65	0.97
No fibrosis (stage 0)	25	17%	869 ms	22.1 ms	364 ms	58.7 ms
Fibrosis (stages 1-4)	30	14%	947 ms	25.0 ms	353 ms	55.2 ms
p-value	-	0.398	0.04	0.003	0.99	0.11
Fibrosis (stage 0-2)	49	17%	913	22.9 ms	360 ms	57.7 ms
Advanced fibrosis (stage ≥ 3)	6	6%	1052	28.9 ms	337 ms	52.3 ms
p-value	-	0.004	0.14	0.002	0.33	0.02

Table 2: Median values and p-values for the patient subsets examined

Refs: 1) Bydder M, Magn Reson Imaging 2008; 26: 847. 2) Vanhamme L, J Magn Reson 1997; 129: 35. 3) Naressi A. MAGMA 2001; 12: 168-76. 4) Hamilton G, NMR Biomed 2011; 24: 784.