

The usefulness of the apparent diffusion coefficient value for the differentiation between ovarian polypoid endometriosis and ovarian endometrioma with malignant tumor

Eito Kozawa¹, Masahiro Takahashi², Yusuke Watanabe², Masanori Yasuda², Keiichi Fujiwara², and Fumiko Kimura²

¹Saitama Medical University, International Medical Center, Hidaka-shi, Saitama, Japan, ²Saitama Medical University, International Medical Center, Saitama, Japan

Introduction: Diffusion-weighted images are widely used in the early detection of cerebral infarction, and their clinical usefulness has been established. In addition, the apparent diffusion coefficient (ADC) has been reported useful in the qualitative diagnosis of tumors and changes that occur as a result of treatment [1-2]. ADC value is well accepted as a means to differentiate between uterus malignant and benign tumor [3]. However, even with MRI, determining the cause of ovarian tumors remains problematic [4]. It is difficult to differentiate between ovarian polypoid endometriosis (OPE) and ovarian endometrioma with malignant tumor (OEMT) because both the tumors contained solid components [5]. We evaluated ADC values whether we could differentiate between OPE and OEMT.

Materials and Methods: Between April 2007 and October 2013, we identified 26 patients with confirmed 20 OEMT and 6 OPE by surgery. The ages of the patients ranged from 32 to 79 years (mean age: 51 years). MR images were obtained by using 1.5T, or 3.0 Tesla superconducting units. Spin-echo T1-weighted images, fast spin-echo T2-weighted images, contrast-enhanced T1-weighted images without fat saturated (FSGDT1WI) and diffusion-weighted images (DWI) with high b-value (b=0, 500 and 1000 sec/mm²) were obtained in all subjects. The patients were divided into two groups. Group 1 comprised 6 patients with 6 OPE and Group 2, 20 patients with 20 OEMT. In visual assessment, each tumor was analyzed for the following categories: the size, the and internal architecture. In quantitative assessment, an ADC map was created with software provided with the MRI scanner, and ADCs were determined by measuring the signal intensity of the solid portions with the map. Means and standard deviations (SD) were calculated for ADC of each group, and means of ADC were compared by Mann-Whitney test using commercially available software (JMP; SAS Institute Inc.). Significance was defined at $P < 0.01$.

Results: The tumor size ranged from 41 to 230 mm (mean; 107mm) at their maximum diameter in OPE and from 90 to 290 mm (mean; 139mm) at their maximum diameter in OEMT. All the tumors appeared as 26 cystic mass with solid-component type (Fig. 1). The mean ADC and SD were: for Group 1, $1.78 \pm 0.38 \times 10^{-5}$ sec/mm² and for Group 2, $1.26 \pm 0.08 \times 10^{-5}$ sec/mm². Quantitative distribution of data via MRI is shown in Fig. 2. Two groups displayed a significant difference in individual Mann-Whitney test results, with a 1% significance level.

Discussion and Conclusion: OPE is relatively common in women of reproductive age and is associated with cancer risk, and it is important to differentiate between OPE and OEMT. In our study, OPE showed a higher ADC than one caused by OEMT. The reasons why OPE yields high ADC values are that malignancy tumor decreases extracellular in the solid portion and OPE has large extracellular space because OPE has a more normal-appearing morphologic structure in the solid portion.

In conclusion, ADC values in the solid components could have the potential to aid in discriminating between OPE and OEMT. ADC values of OPE yielded high values.

References

1. Asao C et al. AJNR 2006; 26: 1455
2. Kitis O et al. Eur. J Rad 2005; 55: 393
3. Tamai K et al. JMRI 2007; 26:682
4. Thommassin-Naggara I et al. European Rad 2009;19:1544
5. Kozawa E et al. MRMS 2012; 11:201

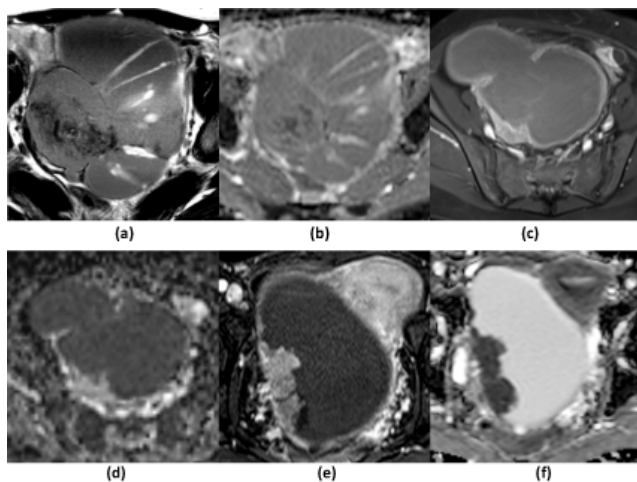


Fig. 1 (a) FSGDT1WI and (b) ADC map; A 46-year-old female, OPE: $ADC=1.82 \times 10^{-3}$ (c) FSGDT1WI and (d) ADC map; A 38-year-old female, OPE: $ADC=2.25 \times 10^{-3}$ (e) FSGDT1WI and (f) ADC map; A 48-year-old female, OEMT

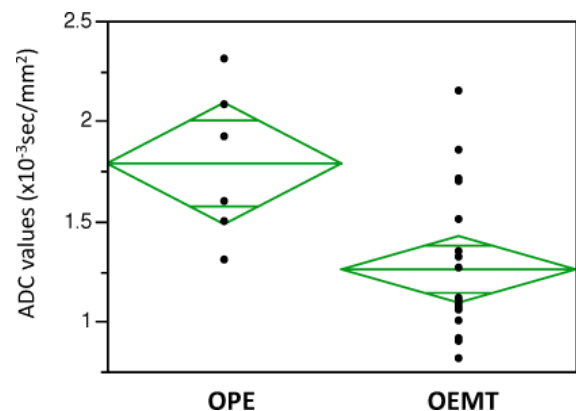


Fig. 2 ADC values of OPE and OEMT
The heights of the diamonds represent the 95% confidence intervals, and the widths of the diamonds are proportional to the sample sizes.