

# Texture analysis of 3T high resolution T2 weighted images in ovarian cystadenoma versus borderline tumour.

Martine Dujardin<sup>1</sup>, Peter Gibbs<sup>1</sup>, and Lindsay W Turnbull<sup>1</sup>

<sup>1</sup>Centre for MR Investigations, University of Hull in association with Hull York Medical School, Hull, United Kingdom

**Target Audience:** Radiologists- MR Physicists- Gynae-oncologists-Gynae-surgeons

## Purpose

Borderline ovarian tumour (BOT) is an ovarian tumour with low malignant potential, representing approximately 15% of all ovarian malignancies [1]. It is important to discriminate BOT from benign lesions, as patients thought to have benign disease only may receive inadequate treatment and limited surgical staging, resulting in the requirement for additional surgical intervention and potential for tumour spread [1]. Preoperative MR diagnosis of BOT is an ongoing challenge and CA-125, the standard marker for epithelial ovarian cancer, is only elevated in 61% [2]. Textural analysis of contrast-enhanced MR images has previously shown significant differences between benign and malignant breast lesions for a number of textural features, including entropy and sum entropy [3]. This study investigates the ability of texture analysis applied to high resolution T2-weighted images, acquired at 3T, to distinguish ovarian cystadenoma from BOT in a limited cohort.

## Methods

35 women (7 bilateral) with histopathologically proven ovarian cystadenoma (N=14; age 56yrs  $\pm$  37) or BOT (N=28; age 53yrs  $\pm$  17) who underwent preoperative conventional pelvic MRI on a 3T MRI system (Discovery 750, GE Healthcare) using a 32-channel phased array coil were retrospectively studied. T2-weighted imaging was performed with the following parameters: TR= 3431 ms, TE= 111 ms, slice thickness= 4 mm, gap= 1 mm, matrix= 512\*416. For the purpose of texture analysis, single slice ROIs, from the most complex portion of the lesion, were drawn manually on the high resolution T2-weighted images by an expert radiologist in gynae-oncology MRI. ROIs were then reduced to 16 grey levels using histogram equalisation to ensure sufficient counting statistics. The 16 texture descriptors f1 to f16 were output using an in house developed software application and were calculated from the spatial gray-level dependence matrix as described by Gibbs et al 2003 [3]. Differences in the 16 textural parameters between cystadenoma and BOT were tested using Mann-Whitney or T-test as appropriate and ROC-curve analysis was performed for the significant finding.

## Results

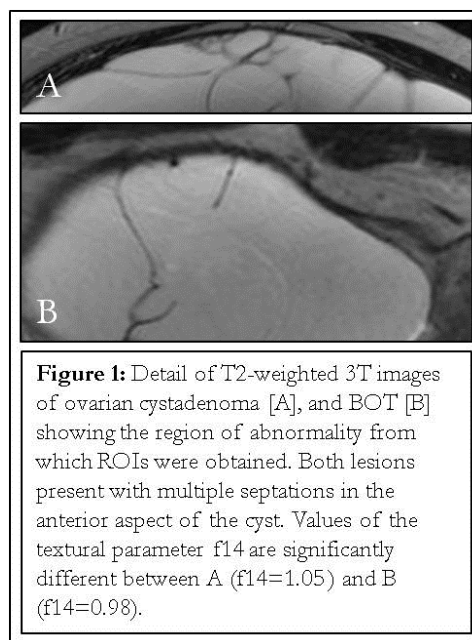
Figure 1 illustrates detail of typical T2-weighted images for cystadenoma and BOT. A significant difference ( $p=0.02$ ) was found for the textural descriptor f14 (maximal correlation coefficient) between the cystadenoma (group average  $1.10 \pm 0.08$ ) and BOT group (group average  $1.05 \pm 0.06$ ). Box plot results for f14 are given in Figure 2. No significant difference was observed in any of the other 15 textural parameters to allow separation of the 2 groups. ROC analysis for f14 results in AUC=0.7.

## Conclusion

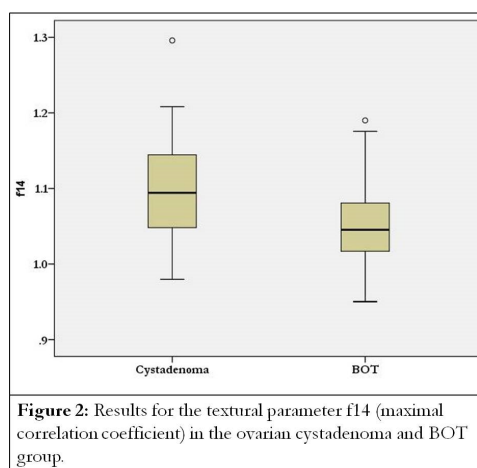
Texture analysis of 3T high resolution T2-weighted images did allow discrimination between ovarian cystadenoma and BOT using f14, leading to a diagnostic accuracy for this textural descriptor of 0.7. Our findings are in line with the results of Gibbs et al. [3] in breast tumours, who found a significant difference in textural features obtained from post contrast imaging of benign and malignant lesions, including entropy and sum entropy. Sensitivity and specificity of MRI for the diagnosis of BOT are 45.5% and 96.1% [4]. No adequately powered prospective study has so far estimated the accuracy of MRI in discriminating BOT from benign lesions [1] Further research is necessary to see whether the addition of textural information to anatomical MR data improves the preoperative differentiation of ovarian cystadenoma from BOT.

## References

- [1] Morotti et al (2012) Arch Gynecol Obstet 285;1103-1112
- [2] Eltabbakh et al (1999) Gynecol Oncol 75:476-479
- [3] Gibbs et al (2003) MRM 50: 92-98
- [4] Spencer et al (2010) Radiology 256;677-694



**Figure 1:** Detail of T2-weighted 3T images of ovarian cystadenoma [A], and BOT [B] showing the region of abnormality from which ROIs were obtained. Both lesions present with multiple septations in the anterior aspect of the cyst. Values of the textural parameter f14 are significantly different between A (f14=1.05) and B (f14=0.98).



**Figure 2:** Results for the textural parameter f14 (maximal correlation coefficient) in the ovarian cystadenoma and BOT group.