

# Volumetric T1 Mapping of liver parenchyma at 3 T: Diagnosing Liver Cirrhosis

Niklas Verloh<sup>1</sup>, Claudia Fellner<sup>1</sup>, Michael Haimerl<sup>1</sup>, Mona Schlabeck<sup>1</sup>, Miriam Rabea Kukach<sup>2</sup>, Marcel D. Nickel<sup>2</sup>, Christian Stroszczyński<sup>1</sup>, and Philipp Wiggermann<sup>1</sup>

<sup>1</sup>Department of Radiology, University Hospital Regensburg, Regensburg, Germany, <sup>2</sup>MR Applications Development, Siemens AG, Healthcare Sector, Erlangen, Germany

## TARGET AUDIENCE

Liver cirrhosis and its evaluation play a significant role in clinical routine. Surgeons require such information for predicting future remnant liver function after partial hepatectomy. In internal medicine, assessment of liver cirrhosis is needed to better predict complications related to hepatic failure. Therefore this study is interesting for clinicians requiring as much information as possible on liver impairment to improve patient care.

## PURPOSE

The purpose of the study was to assess the ability of volumetric T1 mapping of liver parenchyma on gadolinium ethoxybenzyl diethylenetriamine pentaacetic acid (Gd-EOB-DTPA) enhanced 3 T MRI to detect liver cirrhosis.

## METHODS

32 patients (17 men, 15 women; mean age 57 years) underwent MRI on a clinical whole body 3T system (Magnetom Skyra, Siemens Healthcare). To obtain T1 maps a three-dimensional sequence (Vibe 3D: TR, 5.79; TE, 2.46; 3 flip angles, 1°, 7°, 14°; measured voxel size, 3.6mm x 2.5mm x 4.7mm; acquisition time, 17s) with preceding B1-mapping was added to the standard liver imaging protocol at two points in time, one before and the other 20 minutes after Gd-EOB-DTPA administration. The open source OsiriX imaging software (v.5.8 32-bit © Pixmeo Sarl) was used to compute the liver parenchyma volume, as well as the mean T1 relaxation time of the whole liver parenchyma (Fig. 1). The reduction rate (RR) between plain and enhanced T1 relaxation time was calculated using the following formula.

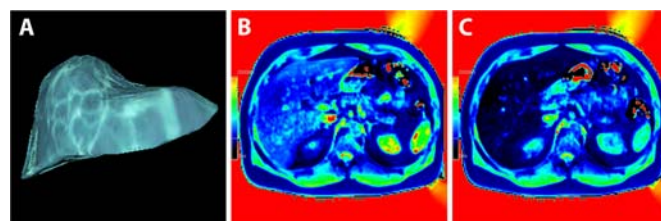
$$\text{reduction rate of T1 relaxation time (RR)} = \left[ \frac{T1(\text{plain}) - T1(\text{enhanced})}{T1(\text{plain})} \right]$$

Patients with and without liver cirrhosis were analyzed regarding their RR during Gd-EOB-DTPA enhanced MRI. The Mann-Whitney-Test was used to compare the analyzed groups.

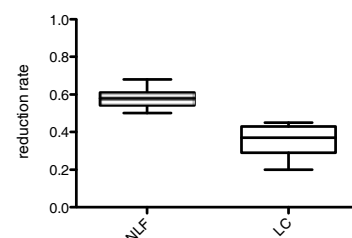
## RESULTS

Mean T1 relaxation time of the three-dimensional sequence for plain MRI was 890.1ms ± 113.9ms, after administration of Gd-EOB-DTPA, mean T1 relaxation time was 459.2ms ± 121.7ms. Plain T1 relaxation time showed no significant (p = 0.676) difference between patients with normal liver function and patients with liver cirrhosis. After the administration of Gd-EOB-DTPA, T1 relaxation times were significantly (p ≤ 0.001) higher for patients with liver cirrhosis (Table 1). The reduction rate of the whole liver (Fig. 2) was significantly (p ≤ 0.001) lower in patients with liver cirrhosis (0.35 ± 0.8) compared to patients with normal liver function (0.58 ± 0.6).

Table 1:	Liver volume [cm <sup>3</sup> ]	T1 relaxation time (plain) [ms]	T1 relaxation time (KM) [ms]	Reduction rate
All (n = 32)	1431	890.1 ± 113.9	459.2 ± 121.7	0.48 ± 0.13
Normal liver (n = 18)	1384	901.3 ± 71.3	378.7 ± 62.5	0.58 ± 0.6
Cirrhotic liver (n = 14)	1491	875.7 ± 154.7	562.7 ± 98.1	0.35 ± 0.8



**Fig. 1: T1 mapping**  
Volume mapping (A) of the three-dimensional T1 mapping Vibe 3D sequence for a patient with a normal liver before (B) and 20 minutes after Gd-EOB-DTPA administration (C).



**Fig. 2: Reduction rate of T1 time**  
Reduction rate between plain and Gd EOB-DTPA-enhanced T1 maps for patients with normal (NLF) and cirrhotic livers (LC).

## DISCUSSION

The hepatocyte-specific contrast agent GD-EOB-DTPA is a contrast medium with T1-shortening effects<sup>(1)</sup> and is taken up into liver parenchyma by active membrane transport systems, such as OATP1 B1/B3<sup>(2)</sup>. Signal intensity in GD-EOB-DTPA-enhanced imaging is highest during the hepatobiliary phase 20 min after contrast medium injection<sup>(3)</sup>, however there is some evidence that the intracellular uptake of Gd-EOB-DTPA is decreased in patients with liver cirrhosis<sup>(4)</sup>. In line with this evidence, we observed that patients with advanced liver disease show a significantly lower reduction rate between plain and enhanced images and therefore have a lower uptake of Gd-EOB-DTPA. It is reasonable to assume that liver cirrhosis causes this reduced reduction rate. Therefore, this reduced reduction rate can be used to detect liver cirrhosis.

## CONCLUSION

The evaluation of changes in T1 mapping of liver parenchyma in Gd-EOB-DTPA-enhanced images may serve as a useful new, non-invasive technique to quantify liver cirrhosis, especially as this new imaging technique displays T1 relaxation time of the whole liver parenchyma and can be acquired in a single breath hold. Another advantage of a three-dimensional image based examination is, that this sequence not only allows us to visualize global, but also partial liver impairment and therefore detect heterogeneous liver diseases.

## REFERENCES

- Seale MK, Catalano OA, Saini S, Hahn PF, Sahani DV. Hepatobiliary-specific MR contrast agents: role in imaging the liver and biliary tree. Radiographics : a review publication of the Radiological Society of North America, Inc. 2009 Oct;29(6):1725-48.
- Tsuda N, Matsui O. Cirrhotic rat liver: reference to transporter activity and morphologic changes in bile canaliculi--gadoxetic acid-enhanced MR imaging. Radiology. 2010 Sep;256(3):767-73.
- Hamm B, Staks T, Muhler A, Bollow M, Taupitz M, Frenzel T, et al. Phase I clinical evaluation of Gd-EOB-DTPA as a hepatobiliary MR contrast agent: safety, pharmacokinetics, and MR imaging. Radiology. 1995 Jun;195(3):785-92.
- Tamada T, Ito K, Higaki A, Yoshida K, Kanki A, Sato T, et al. Gd-EOB-DTPA-enhanced MR imaging: evaluation of hepatic enhancement effects in normal and cirrhotic livers. European journal of radiology. 2011 Dec;80(3):e311-6.