

Diffusion MRI in Crohn's Disease: Comparison with Fecal Calprotectin and MR-Enterography

Douglas Andrew Pendse¹, Jessica Makanyanga¹, Andrew Plumb¹, David Atkinson¹, and Stuart Taylor¹
¹Centre for Medical Imaging, University College London, London, London, United Kingdom

Purpose

Therapeutic strategies in Crohn's disease are dependent on both the degree of disease activity and the overall burden of disease in the gut (1,2). Recent studies have shown that Diffusion Weighted Imaging (DWI) performed as part of Magnetic Resonance Enterography (MRE) is feasible and is able to delineate segments of active inflammation in the bowel (3–8). It is however unknown if this technique is able to characterise the global disease burden or if DWI findings correlate with existing validated measures of global activity such as fecal calprotectin (fC)

Methods:

Institutional and Research Ethics Committee approval was obtained for the study. All patients gave written informed consent. The study was performed at a single institution, a large tertiary teaching-hospital. **Patients:** Patients with a known or suspected diagnosis of Crohn's disease and for whom bowel imaging was clinically indicated, were prospectively recruited into the study. Patients were followed up for a minimum of 6 months to confirm a final diagnosis of Crohn's disease. **MRI Protocol:** Patients were starved for 4 hours prior to MRE, which was performed with oral preparation according to the previously described protocol (9). Both 1.5T Siemens and 3.0T Phillips Achieva MR systems were used. **Fecal Calprotectin:** Patients provided a same-day stool sample, which was used for calprotectin (fC) assay (PhiCal, NovaTec). **DWI Assessment:** MRE data were reviewed by 2 sub-specialist radiologists in consensus. DWI images (b0,50,100,300,600,800) were scored with respect to signal intensity to assess for disease presence and activity on a 4-point scale from the most abnormal areas (0=Normal, 1=Probably normal, 2=Probably abnormal, 3=Abnormal). Disease burden was assessed by distribution of DWI signal abnormality as either <10cm small bowel, >10cm small bowel, small and large bowel disease and isolated colitis. A previous validated MRI score of global activity based on conventional T1 and T2 weighted images was used; including qualitative assessment of segmental mural thickness, T2 signal, contrast enhancement, extra-mural complications such as fistulae, and disease length (Magnetic Resonance Enterography Global Score) MEGS (9) was applied by different observers. Statistical analysis comparing presence and extent of abnormality on DWI, and calprotectin levels and MEGS score was undertaken using the Wilcoxon rank-sum test for unpaired comparisons and Kruskal-Wallis 1-way analysis of variance.

Results

80 patients were recruited into the study and underwent MRE, of which 71 had a proven diagnosis of Crohn's disease. 69 patients had diffusion imaging and were included in the analysis. Mean fC score was 398ug/g (range <19 to 1970ug/g), fC was raised (>120ug/g) in 44/69 (64%) patients. DWI was scored in 20 patients as *Normal* or *Probably normal*, 17 as *probably abnormal* and 32 as *abnormal*. Patients defined as *P.Abnormal/Abnormal* on DWI was significantly higher fC and MEGS scores in comparison to those defined as *Normal/P.Normal* on DWI (21.9 ± 12 vs 3.3 ± 5.5 , $P=0.0002$ and 492 ± 422 ug/g vs 159 ± 257 ug/g, $p<0.0001$). Both MEGS and Fc were significantly different between cohorts grouped according to the extent of DWI abnormality ($P<0.0001$) and ($p=0.02$) respectively (see figure) When using 120ug/g as a limit for normal, DWI has sensitivity 84% and specificity 52% for intestinal inflammation.

Discussion and Conclusion

In this study we have evaluated the signal intensity of the bowel wall on diffusion-weighted MRI in a population with Crohn's disease. We have not evaluated a quantitative measure of diffusion (such as ADC) and have not separated our evaluation by bowel segments. The data show that patients with abnormal bowel on DWI analysis have significantly increased calprotectin, a marker of intestinal inflammation. A greater extent of DWI abnormality is also associated with increased calprotectin levels and previously validated MRI scores based on conventional image sequences. Diffusion imaging of the bowel, analysed with the methods described, is a relatively fast and easy way of screening for inflammation in the bowel. These data suggest that diffusion MRI is a clinically useful tool in the evaluation of Crohn's activity.

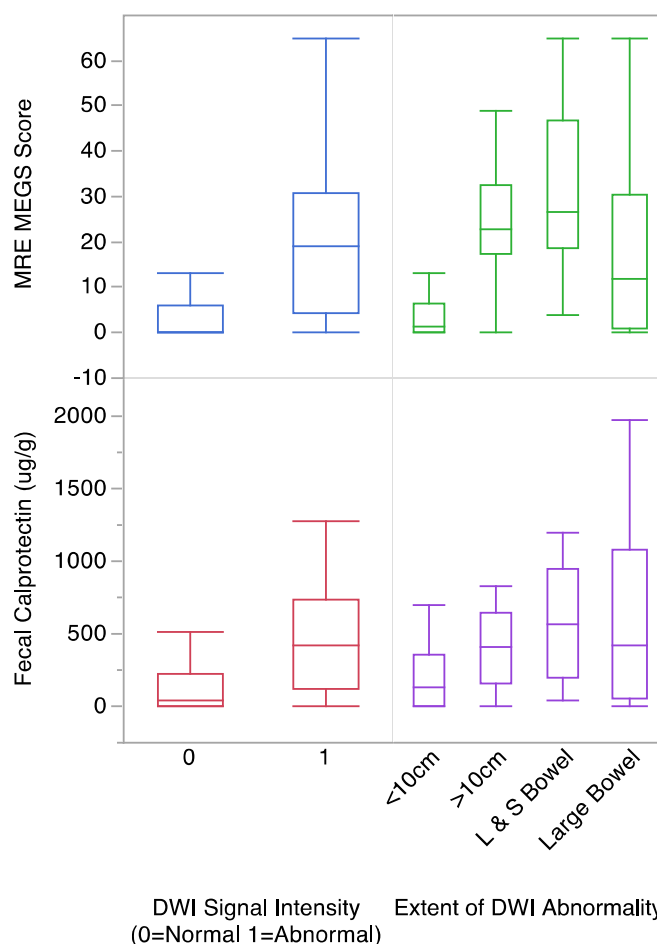


Figure 1: Fecal Calprotectin and MEGS score vs DWI Signal Intensity and Extent of DWI abnormality

References: [1] Lichtenstein et al. Am. J. Gastro. 2009 Feb;104(2):465–83 [2] Dignass A et al. J. Crohns. Colitis 2012 Dec ;6(10):965–90. [3] Buisson a et al. Alim. Pharml. Ther. 2013 Mar;37(5):537 [4] Kiryu S et al. F. J. Magn. Reson. Imaging 2009 Apr;29(4):880 [5] Maccioni F et al. Abdom. Imaging 2012 Dec ;37(6):974–82. [6] Oto A et al. Acad. Radiol. 2009 May;16(5):597–603 [7] Oussalah A et al. Gut 2010 Aug ;59(8):1056–65. [8] Punwani S et al. Proc. ISMRM 2009 Apr 22 [9] Makanyanga et al. Eur. Radiol. 2013 Sep 12 [Epub ahead of print]