

## Cine MRI Evaluation of Intestinal Motility in Neonates: A Feasibility Study

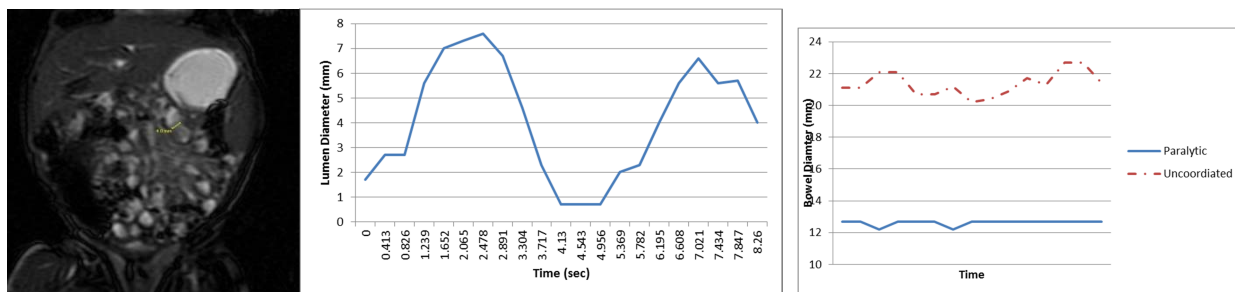
Jean A Tkach<sup>1</sup>, Mantosh S Rattan<sup>1</sup>, Charles L Dumoulin<sup>1</sup>, and Andrew P South<sup>2</sup>

<sup>1</sup>Radiology, Cincinnati Children's Hospital Medical Center, Cincinnati, Ohio, United States, <sup>2</sup>Neonatology and Pulmonary Biology, Cincinnati Children's Hospital Medical Center, Cincinnati, Ohio, United States

**Purpose:** To determine the feasibility and utility of cine MRI to assess intestinal motility in neonates.

**Materials and Methods:** Cine MRI abdominal data sets were obtained in seven neonates with no history of abdominal pathology (normal) and two infants with gastroschisis (GS), a congenital anomaly known to adversely affect intestinal motility. All infants were late preterm or term at the time of imaging. MR imaging was performed free breathing and without sedation on a small footprint (21.8cm bore diameter without RF coil; 51.8cm long) 1.5T hybrid ONI/GE HDx MRI system designed specifically for imaging neonates within our NICU<sup>1,2</sup>. IRB approval and written informed consent was obtained from the parents prior to imaging. Infants were scanned supine and, if not NPO for clinical reasons, fed 30 to 60 minutes prior to the exam. Coronal 5mm balanced steady state images were acquired at a temporal resolution of approximately 0.5s/image over 16-52s from 3-5 locations in the abdomen. 1-3 segments of well-distended bowel were selected in each data set. Manual measurements of the cross-sectional diameter of each segment were recorded for each time point. Motility patterns were evaluated qualitatively (paralytic, quivering, uncoordinated or sinusoidal)<sup>3</sup> and quantitatively (contraction frequency (determined using Lomb Scargle Periodogram analysis<sup>4</sup>), amplitude and ratio) and their relationship to concurrent clinical data was explored.

**Results:** Motility data was obtained in 7 normal and 2 GS infants. 2 of the 7 normal motility data sets were eliminated due to inadequate distension, excessive bowel gas, or out of plane motion. Motility plots of normal infants exhibited a sinusoidal pattern (Fig. 1a) with mean frequency of  $11.1 \pm 1.7$  [range 9.3 -12.9] contractions per minute (Fig 1 a,b). These findings are consistent those reported in adults<sup>5</sup>. Intestinal motility in GS infants included paralytic, quivering, uncoordinated (Fig 1c) patterns. The observed pattern related to the concurrent degree of abnormal bowel distension or clinical status (e.g. volume of enteral feeds). Intestinal motility patterns were typically complex and erratic. Pauses in between successive periods of sinusoidal contraction were often observed. Hence, cine data collection over the longer periods of time was beneficial as the use of Lomb Scargle periodogram to extract contraction frequency from the often complex and weakly periodic motility waveforms<sup>4</sup>.



**Discussion:** Preterm and term neonates are at high risk of intestinal motility disorders. In older children and adults, cine MRI has proven useful in diagnosis and management of intestinal motility disorders<sup>5-8</sup>. However, standard technique includes prone positioning, breath holding and oral bowel preparation—techniques that cannot safely or practically be applied to neonates. Despite these challenges, the results of the present study suggest that cine MRI can be successfully applied in neonates to evaluate intestinal motility. Although demonstrated on a small footprint scanner, the technique can be implemented on adult sized scanners. Future improvements to the neonatal application include the use of semi automatic intestinal motility analysis with respiratory motion correction such as that developed and demonstrated in adults<sup>9</sup>.

**Conclusions:** Cine MRI is a viable method to assess intestinal function/motility in neonates. Further studies to evaluate its efficacy in the diagnosis of intestinal dysfunction and abdominal pathology associated with prematurity are warranted.

**References:** <sup>1</sup>Tkach JA, et al. 2012 Ped Rad (2012) 42:1347-1356, <sup>2</sup>Tkach, JA et al., AJR (In Press). <sup>3</sup> Bickelhaupt S et al, MRM (2013) hdoi.org/10.1002/mrm.24708, <sup>4</sup>Patak M, et al. Gut 2007;56: 1023–1025, <sup>5</sup>Ohkubo et al. American J Gastroenterol 2013;108:1130-1139, doi.1038/ajg.2013.5, <sup>6</sup> Buhmann-Kirchhoff et al. Eur Radiol (2008) 18: 1215–1223, <sup>7</sup> Menys et al, Eur Radiol (2012) 22:2494–2501, <sup>8</sup>Bickelhaupt et al, Clinical Radiology (2013), <http://dx.doi.org/10.1016/j.crad.2013.06.024>, <sup>9</sup>Bickelhaupt et al, Magn Reson Med 2013. <http://dx.doi.org/10.1002/mrm.24708>.