

Diffusion tensor imaging detects demyelination and axonal injury in mouse spinal cord

Nabeela Nathoo¹, Dayae Jeong², Michael B. Keough³, Tad Foniok¹, V. Wee Yong³, and Jeff F. Dunn^{1,4}

¹Radiology, University of Calgary, Calgary, Alberta, Canada, ²Rice University, Houston, Texas, United States, ³Clinical Neurosciences, University of Calgary, Calgary, Alberta, Canada, ⁴Experimental Imaging Centre, University of Calgary, Calgary, Alberta, Canada

Target audience: Those using diffusion tensor imaging (DTI) for assessing demyelination and/or axonal damage in spinal cord.

Purpose: To show scalar measures obtained with DTI can detect demyelination and axonal damage.

Methods: Focal demyelination was induced in C57BL/6 mice by injecting lysolecithin in the dorsal column of the spinal cord.^{1,2} Mice were sacrificed at 7 days (n=11, time of maximal demyelination) and 14 days post-injection (n=7, ongoing remyelination). Naive and sham cords were included (n=5 per group). Cords were fixed in 4% PFA then transferred to 30% sucrose for ≥ 48 hours before imaging. Before imaging, cords were rinsed, incubated in a 1:200 solution of gadolinium:PBS for 45 mins, then embedded in agarose gelatin.³ DTI EPI was done on a 9.4T Bruker Avance II console with a 35mm volume coil (matrix=128x128, FOV=1.5cmx1.5cm, TE/TR=35.66/5000ms, 15 directions, 4 segments, NEX=12, slice thickness=0.5mm). MedINRIA software was used for analysis. ROIs were drawn within and anterior to the lesion. Fractional anisotropy (FA), axial diffusivity (AD), radial diffusivity (RD) and mean diffusivity (MD) were measured. One-way ANOVA with Tukey's post-hoc test was used to compare naive, sham, 7 day and 14 day lysolecithin data for each scalar measure.

Results: Tractography showed the demyelinated lesion as a gap devoid of white matter tracts 7 days after lysolecithin injury (**Fig. 1**). In the lesion area, RD was significantly different between groups ($p=0.003$). RD at 7 days after lysolecithin injury was significantly higher than naive ($p=0.006$) and sham controls ($p=0.022$), but was not significantly different than at 14 days (**Fig. 2**). MD was significantly different between groups ($p=0.025$); MD at 7 days after lysolecithin injury was significantly higher than MD in naive cords ($p=0.046$), but not for any other comparisons (**Fig. 2**). AD was not significantly different between groups (**Fig. 2**). FA was significantly different between groups ($p<0.001$). FA at 7 days after lysolecithin injury was significantly lower than FA at 14 days ($p<0.001$), in naive cords ($p<0.001$) and in sham cords ($p<0.001$) (**Fig. 3**). Anterior to the lesion, AD was significantly different between groups ($p=0.036$), and specifically between 7 day and 14 day lysolecithin cords ($p=0.027$) (**Fig. 4**). No other scalar measures were significantly different between groups anterior to the lesion.

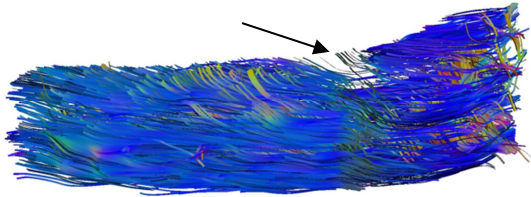


Fig 1. Tractography shows a gap in white matter tracts 7 days after lysolecithin-induced demyelination (black arrow).

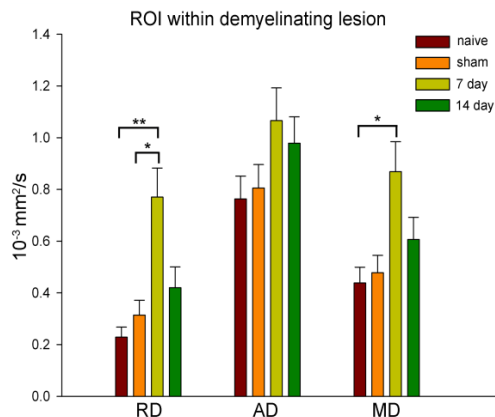


Fig 2. RD, AD and MD in LA for naive, sham, 7 days and 14 days after lysolecithin-induced demyelination. RD is significantly higher 7 days after lysolecithin injury than in naive and sham cords. MD is significantly higher at 7 days after lysolecithin injury than in naive cords. * $p<0.05$ and ** $p<0.01$ by one-way ANOVA with Tukey's post-hoc test.

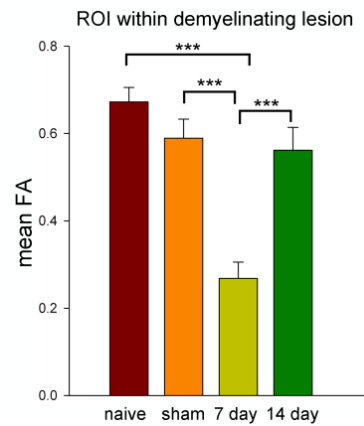


Fig 3. FA is significantly reduced at 7 days, but not at 14 days after lysolecithin-induced demyelination. *** $p<0.001$ by one-way ANOVA with Tukey's post-hoc test.

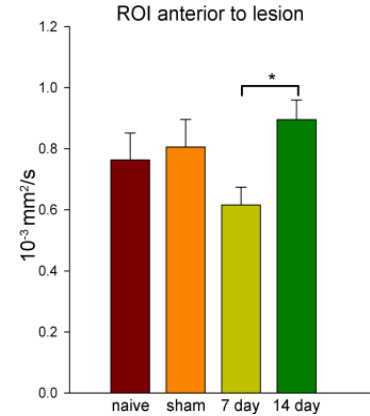


Fig. 4. Anterior to the lesion, AD is significantly lower 7 days after lysolecithin-induced injury. * $p<0.05$ by one-way ANOVA with Tukey's post-hoc test.

Discussion: At 7 days post-injury there were increases in RD and MD, while FA declined. Such changes are indicative of demyelination, as reported by others.⁴ Normalization of scalar measures 14 days after lysolecithin injury is likely due to remyelination. There is a decrease in AD in the area anterior to the lesion at 7 days after lysolecithin injury which normalizes by 14 days. This may be due to axonal injury and subsequent recovery.

Conclusion: Scalar measures obtained using DTI can be used to assess demyelination and axonal damage in a mouse model of focal white matter demyelination in the spinal cord. This supports the use of DTI as a measure of demyelination and damage in cord.

References:

1. Lau L, Keough MB, Haylock-Jacobs S, et al. *Ann Neurol.* 2012;72:419-432.
2. McCreary CR, Bjarnason TA, Skihar V, et al. *Neuroimage.* 2009;45:1173-1182.
3. Ellingson EM, Kurpad SN, Schmit BD. *JMRI.* 2008;28:1068-1079.
4. DeBoy CA, Zhang J, Dike S, et al. *Brain.* 2007;130:2199-2110.