

# BBB Breakdown due to Axonal Degeneration: A Potential Confounding Factor for MS Diagnosis

Shu-Wei Sun<sup>1,2</sup>, Christopher Nishioka<sup>3</sup>, Steven Kaspick<sup>4</sup>, Chen-Fang Chung<sup>4</sup>, JoAnn Park<sup>4</sup>, and Hsiao-Fang Liang<sup>4</sup>

<sup>1</sup>Loma Linda University, Loma Linda, CA, United States, <sup>2</sup>University of California, Riverside, Riverside, CA, United States, <sup>3</sup>University of California, Riverside, CA, United States, <sup>4</sup>Loma Linda University, CA, United States

## Introduction

Multiple Sclerosis (MS) is generally considered a disease caused by immune disorders to attack myelin leading to inflammation and axonal damage. MRI contributes critical information for MS diagnosis. In particular, the Gd-enhanced T1-weighted imaging (Gd-T1WI), detects the leakage of the blood-brain-barrier (BBB), which is related to T-cell infiltration along with severe inflammatory and usually considered the “active” lesion, representing the initial insult or the relapsing phase along the disease progress of MS [1]. The question is, does the bright Gd-T1WI only appear at the initial insults? In MS, focal white matter damage can cause axonal degeneration which may propagate along axons leading to a remote axonal damage. We argue that remote axonal degeneration can also cause BBB breakdown, which may appear as bright Gd-T1WI to confuse the MS diagnosis.

## Materials and Methods

Retinal ischemia (RI) was induced in mice to cause damage in retinal ganglion cells (RGC) leading to degeneration in optic nerves (ON) and tracts (OT) [2] of six Slow Wallerian Degeneration (WldS) and six wild-type mice. RI was performed in the right eyes, leaving the left eyes intact. Longitudinal Diffusion Tensor Imaging (DTI) was performed, using a Bruker 4.7T BioSpec with TR 2 s, TE 29 ms,  $\Delta$  20 ms,  $\delta$  3 ms, 6 gradient directions with  $b$  0.85 ms/ $\mu$ m<sup>2</sup> and 1 b0, NT 3, Slth 0.5 mm, FOV 1.5 cm x 1.5 cm, and matrix 128 x 128. Using another group of mice, animals were treated with retina ischemia and the BBB integrity was examined using Gd-T1WI and Evans Blue.

## Results

Following RI, both WldS and wild-type developed damage in ON and OT, while the damage was delayed in WldS. In WldS, ON and OT showed significant reductions of axial diffusivity in weeks 1 and 2, respectively. In contrast, both ON and OT were injured in day 3 in wild-type mice (Fig. 1). WldS provided us the time window of distinguished injury severity between the proximal (ON) and distal sections (OT) of RGC axons. Gd-T1WI and Evans blue both showed significant BBB leakage in RI-affected ON and OT beginning at week 1 in WldS mice (Figs. 2 and 3).

## Discussion

Gd-T1WI-detected BBB leakage has been used to indicate the initial damage or relapsing events in MS. Our data showed that degenerated axons in the remote sites can also cause BBB leakage. The remote BBB leakage may be observed in Gd-T1WI and may confuse the MS diagnosis. More surprisingly, such BBB leakage at the remote sites may occur before the axonal degeneration approached. In RI-affected optic tract of WldS mice, axonal degeneration did not occur until 2 weeks after RI. In contrast, BBB leakage was observed in 1 week. We suspected that the astrocytic networks might trigger the remote responses, which may disturb BBB before the actual degeneration arrived.

## References:

[1] Miller DH et al, Ann Neurol 2004;56:273–278). [2] Sun SW et al, Neuroimage 2008;40:1–10.

**Acknowledgement:** NIH R01 NS062830.

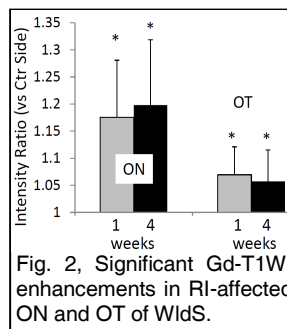


Fig. 2, Significant Gd-T1WI enhancements in RI-affected ON and OT of WldS.

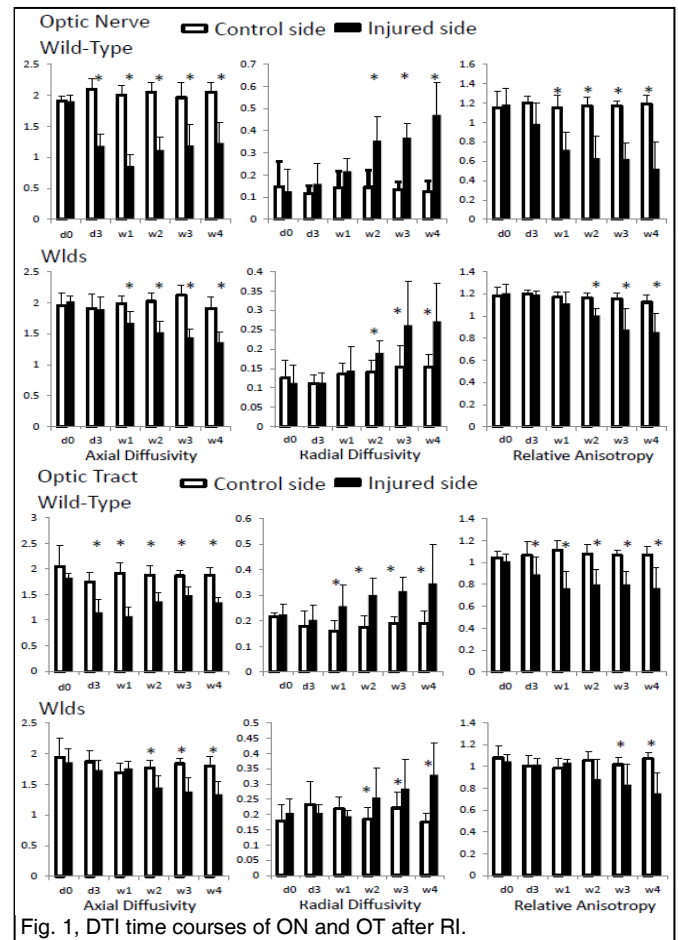


Fig. 1, DTI time courses of ON and OT after RI.

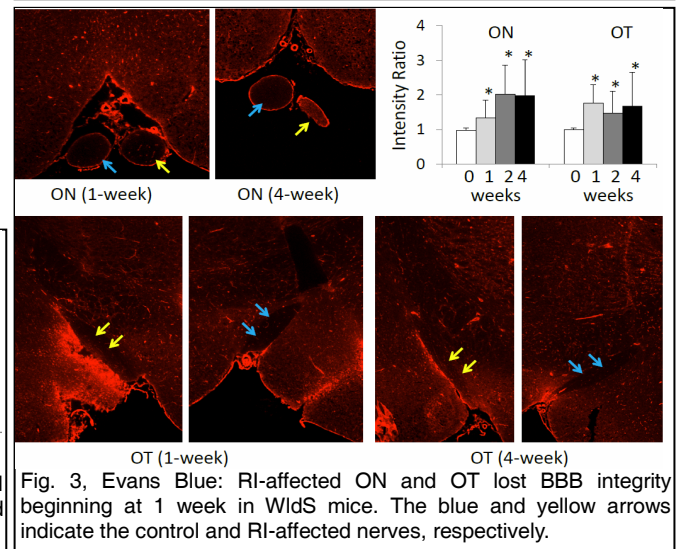


Fig. 3, Evans Blue: RI-affected ON and OT lost BBB integrity beginning at 1 week in WldS mice. The blue and yellow arrows indicate the control and RI-affected nerves, respectively.