

Cerebrovascular reactivity as objective markers of hemodynamic compromise: A pilot study

Olivia Sobczyk^{1,2}, Daniel M. Mandell², Kevin Sam^{2,3}, Adrian Crawley², Julien Poubanc², David Mikulis², James Duffin^{3,4}, and Joseph Fisher^{3,4}

¹Institute of Medical Science, University of Toronto, Toronto, Ontario, Canada, ²Department of Medical Imaging, University Health Network, Toronto, Ontario, Canada, ³Department of Physiology, University of Toronto, Toronto, Ontario, Canada, ⁴Anaesthesiology, University Health Network, Toronto, Ontario, Canada

PURPOSE: To assess the ability of cerebrovascular reactivity (CVR) to identify hemodynamically significant steno-occlusive vascular disease.

INTRODUCTION: We measured CVR as the change in BOLD MRI signal (ΔS), a surrogate for the change in regional cerebral blood flow, in response to a standardized increase in the end-tidal partial pressure of CO_2 (PETCO_2), i.e., $\text{CVR} = \Delta S / \Delta \text{PETCO}_2$. Although the ranges of pathological CVR values greatly overlap normal CVR values in various brain regions we nevertheless hypothesized that in patients with steno-occlusive cerebrovascular disease, including those with normal vascular reactivity, CVR would discriminate between those with, and those without, hemodynamically significant disease.

METHODS: We formed an atlas by calculating the normal range of CVR voxel-by-voxel, in a cohort of 44 healthy subjects. Each CVR value was mapped to its anatomical scan, which was coregistered to a standard space. Thus the atlas consisted of means and standard deviations of CVR for each voxel. We identified 30 patients from our CVR research database that had symptomatic cerebrovascular steno-occlusive disease. Patient scans were co-registered to the same space as the atlas, and their CVR values were scored by assigning a z-score according to the mean and standard deviation of the corresponding voxel of the atlas. Since the middle cerebral artery (MCA) carries 80% of cerebral blood flow, we calculated average z-scores for left and right MCA territories, in each subject. In order not to prejudge the assessment, each subject's MCA territories were further classified only into "higher" and "lower" average z-scores, regardless of which side. Then all 4 categories were analyzed according to their frequency distribution histograms.

RESULTS: As Figure 1 shows, there was no difference between the high and low categories in the healthy control subjects. In patients there was a marked reduction in average z-scores ipsilateral to stenosis. In the contralateral hemisphere, the often normal-appearing MCA CVR was reduced relative to healthy subjects.

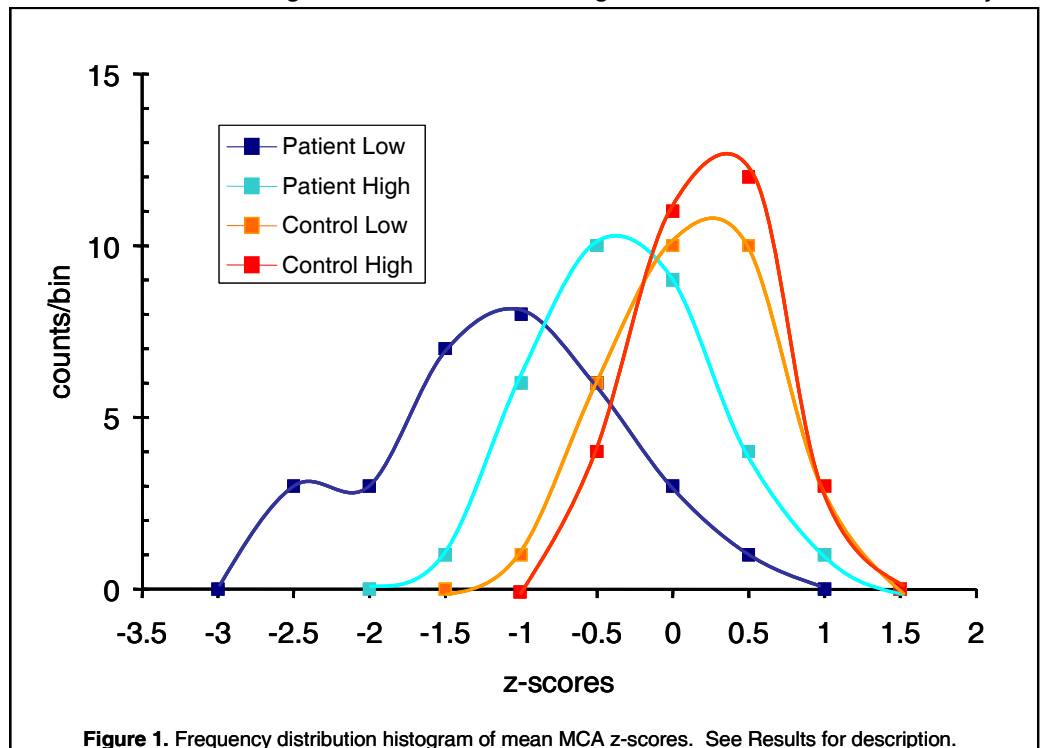


Figure 1. Frequency distribution histogram of mean MCA z-scores. See Results for description.

DISCUSSION/CONCLUSION: This study is the first application of voxel-by-voxel scoring of the differences of BOLD MRI CVR between an individual and a healthy cohort in the assessment of hemodynamic compromise of steno-occlusive disease. The small area under the overlap between the healthy cohort and the worse affected MCA territory suggests a high sensitivity and specificity of this approach. Further independent investigation of the hemodynamic status of the MCA territories and refinement of the method to reduce variability in CVR are required before the sensitivity and specificity of this technique can be quantified.