

Voxel-based comparison of Dynamic Contrast-Enhanced MRI and FDG-PET in head-and-neck cancer

Petra van Houdt¹, Britt Kunnen¹, Olga Hamming-Vrietze¹, Jeroen van de Kamer¹, and Uulke van der Heide¹
¹Radiation Oncology, the Netherlands Cancer Institute, Amsterdam, Netherlands

Purpose

Both FDG-PET and dynamic contrast-enhanced (DCE-) MRI can be useful to characterize radio-resistant parts of tumors in head-and-neck cancer. Previous studies carried out at patient-level showed mixed results about the correlations between standardized uptake values (SUV) and DCE pharmacokinetic parameters. For primary tumors a significant correlation was reported between SUV and one of the DCE parameters (v_e)¹, whereas no correlation was obtained for nodal metastases². In this study we test the hypothesis that a voxel-based comparison will result in stronger correlations, because tumor heterogeneity is taken into account.

Methods

Twenty-one patients with head-and-neck cancer were retrospectively selected for whom a planning CT, FDG-PET/CT and DCE-MRI exam prior to radiotherapy were available. FDG-PET was performed one hour after injection of FDG (voxel size $2 \times 2 \times 2$ mm³). SUV maps were used for subsequent analysis. The DCE-MRI exam was performed on a 1.5T MR scanner with flex coils using a transversal 3D spoiled-gradient echo sequence (voxel size $3 \times 3 \times 4$ mm³, 29 slices, TR/TE 4.0/1.16 ms, flip angle 15 degrees; dynamic scan time 2.5 s, no. of volumes 60). The contrast agent (Dotarem, 15 mL) was injected at a flow rate of 3 mL/s using a power injector followed by a saline flush. The signal intensities were first converted to gadolinium concentration using a pre-contrast T₁ map estimated from a variable flip angle series of 3, 6, 10, 20 and 30 degrees. The extended Tofts model was fitted to the concentration time curves for estimation of the pharmacokinetic parameters (K^{trans} , k_{ep} , v_p , and v_e)³. A population-based arterial input function was used derived from the combined magnitude and phase data in the external carotid arteries in the neck of the patients. Patients were positioned in their radiotherapy mask during all examinations, except for six FDG-PET scans. All images were rigidly registered to the planning CT using a large region of interest containing the spinal cord, mandible and part of the skull. SUV and DCE parameter maps were compared at voxel-level and at patient-level. For the comparison at voxel-level Spearman's correlation coefficient (ρ) was calculated between SUV and each of the DCE parameter values for all voxels within the gross tumor volume (GTV) for each patient separately. A two-sided Wilcoxon signed-rank test was used to test whether the average correlation coefficient across all patients was significantly different from zero. For the comparison at patient-level, ρ was calculated between median SUV values and median DCE values across all patients.

Results

The average median SUV value within the GTV was 4.6 ± 1.6 , whereas the average median pharmacokinetic values of the Tofts model were 0.48 ± 0.16 min⁻¹ for K^{trans} , 1.30 ± 0.27 min⁻¹ for k_{ep} , 0.34 ± 0.12 for v_e and 0.06 ± 0.01 for v_p . The correlation between SUV and K^{trans} was higher and significant at voxel-level compared to patient-level, $\rho = 0.25$ vs. $\rho = 0.16$. The same result was obtained for the correlation between SUV and k_{ep} ($\rho = 0.42$ at voxel-level, $\rho = 0.19$ at patient-level). These correlations were not dependent on the size of the tumor. v_e and v_p were not significantly correlated to SUV at both levels (Table 1). Fig. 1 illustrates the positive correlation between SUV and K^{trans} and k_{ep} . However, it should be noted that the results are variable among patients (Fig. 2).

Discussion

The average SUV and DCE parameter values were in accordance with previously reported primary tumor values¹. Also the results at patient-level were comparable to previous results, except that Bisdas et al. reported a significant correlation between SUV and v_e ¹. At voxel-level our results show a positive correlation between SUV (indicative for metabolic activity) and K^{trans} (representing vessel permeability) and k_{ep} (representing wash-out).

Conclusion

At voxel-level the correlations within the GTV for head-and-neck cancer were higher between SUV and K^{trans} and k_{ep} compared to the results at patient-level. Therefore, tumor heterogeneity should be taken into account. However, the correlations are moderate indicating that FDG-PET and DCE-MRI provide partly complementary information.

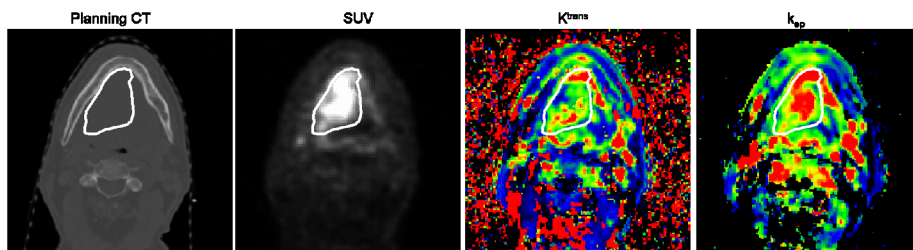


Fig. 1 Patient example of comparison between SUV, K^{trans} , and k_{ep} . White contour line indicates the GTV. For this patient ρ between SUV and K^{trans} was 0.30, whereas ρ between SUV and k_{ep} was 0.66.

Table 1 Spearman's correlation coefficients for comparison between SUV and DCE parameters at voxel-level and at patient-level (* $p < 0.01$)

	Median ρ voxel-level (range)	ρ patient-level
SUV vs. K^{trans}	0.25* (-0.25 – 0.52)	0.16
SUV vs. k_{ep}	0.42* (-0.31 – 0.66)	0.19
SUV vs. v_e	0.013 (-0.40 – 0.43)	0.26
SUV vs. v_p	0.13 (-0.25 – 0.35)	0.22

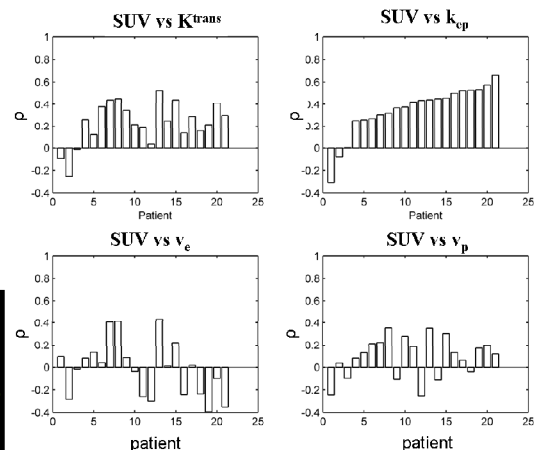


Fig. 2 Spearman's correlation coefficients between SUV and DCE parameters at voxel-level for all patients.

References

- [1] Bisdas S, Seitz O, Middendorp M, et al. An exploratory pilot study into the association between microcirculatory parameters derived by MRI-based pharmacokinetic analysis and glucose utilization estimated by PET-CT imaging in head and neck cancer. *Eur Radiol.* 2010; 20:2358-2366;
- [2] Jansen J, Schöder H, Lee N, et al. Tumor metabolism and perfusion in head and neck squamous cell carcinoma: pretreatment multimodality imaging with ¹H magnetic resonance spectroscopy, dynamic contrast-enhanced MRI, and [¹⁸F]FDG-PET. *Int J Radiation Oncology Biol Phys.* 2012; 82:299-307;
- [3] Murase K. Efficient method for calculating kinetic parameters using T₁-weighted dynamic contrast-enhanced magnetic resonance imaging. *Magn Reson Med.* 2004; 51:858-862