

Cerebrovascular reactivity quantification in patients with intracranial stenosis before and after surgical revascularization

Carlos C. Faraco¹, Lindsey M. Dethrage¹, Meaghan A. Neill², Lori C. Jordan³, Robert J. Singer⁴, J Mocco⁵, Paul F. Clemmons⁶, Manus J. Donahue^{1,3}, and Megan K. Strother¹

¹Department of Radiology and Radiological Sciences, Vanderbilt University, Nashville, TN, United States, ²The Medical University of South Carolina, Charleston, SC, United States, ³Department of Neurology, Vanderbilt University, Nashville, TN, United States, ⁴Section of Neurosurgery, Geisel School of Medicine at Dartmouth, Hanover, NH, United States, ⁵Department of Neurosurgery, Vanderbilt University, Nashville, TN, United States, ⁶Department of Radiology Nursing, Vanderbilt University, Nashville, TN, United States

Target Audience: Stroke clinicians and researchers interested in application of novel MRI approaches for longitudinal monitoring of ischemia.

Purpose: Effective stratification and longitudinal monitoring of cerebrovascular reactivity (CVR) in patients at risk for stroke is critical to guiding management decisions. Currently, longitudinal monitoring of cerebrovascular compromise typically occurs through invasive angiographic methods. While providing crucial information regarding steno-occlusive extent, angiography provides no quantitative or descriptive information regarding tissue-level functioning and commonly (i.e., digital subtraction angiography or CT angiography) requires ionizing radiation and/or exogenous contrast, and thus is suboptimal for routine patient monitoring. Alternatively, hypercarbic hyperoxia (i.e., carbogen) administration can be used to elicit changes in CVR that can be evaluated non-invasively using hemodynamic-weighted functional MRI¹. As carbogen increases oxygen delivery to tissue, it is potentially safer than CVR measurements derived from pharmacological agents. Despite these advantages, very little information is available on the stability of this technique over time and its abilities to detect changes in response to therapy. To understand the effectiveness of this method, we have implemented BOLD fMRI in a major university hospital to longitudinally monitor CVR in non-atherosclerotic (i.e., Moyamoya) intracranial stenosis patients. Importantly, a clear time-frame indicating periods of expected improvement in CVR following indirect revascularization in this population is unclear. Here, hypercarbic hyperoxic BOLD is used to delineate a possible time-frame by serially evaluating Moyamoya patients post-surgery.

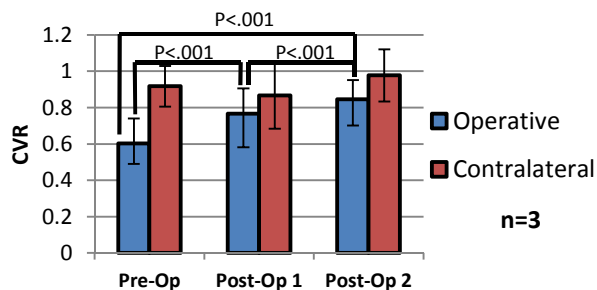


Fig.1. CVR, as measured by occipital lobe-normalized BOLD Z-statistics, for 3 patients scanned pre- and post-op demonstrating longitudinal CVR improvement in the operative hemisphere.

occipital lobe vasculature was preserved in patients, as documented by angiography. Z-statistics were found to be preferable to absolute signal changes as they reduced low SNR contrast from draining veins derived from hyperoxic-induced increases in blood oxygenation.

Results: Z-statistics for patients with pre- and post-revascularization scans indicated that CVR was significantly improved ($p<.001$) after the first follow-up scan (4.3 ± 1.5 months post-op) and continued to improve ($p<.001$) for the second follow up scan (17 ± 5 months post-op; Fig.1). Furthermore, CVR significantly improved ($p<.001$) in the contralateral hemisphere in the second follow-up scan. Grouping all ten patients' scans by time since revascularization indicated that significant CVR ($p<.001$) improvements in the operative hemisphere may not appear until more than one year post-op (Fig. 2). Fig. 3 depicts group averaged images for the following time periods: pre-op (18 ± 21 days, 6 hemispheres), less than 1 year post-op (4.7 ± 1.6 months, 6 hemispheres), between 1 to 2 years post-op (16.6 ± 3.9 months, 8 hemispheres), and more than two years post-op (35.4 ± 11.3 months, 11 hemispheres). It should be noted that two patients experienced significantly reduced CVR ($p<.001$) in an operative hemisphere, in relation to their previous scan, at 25 and 39 months post-op.

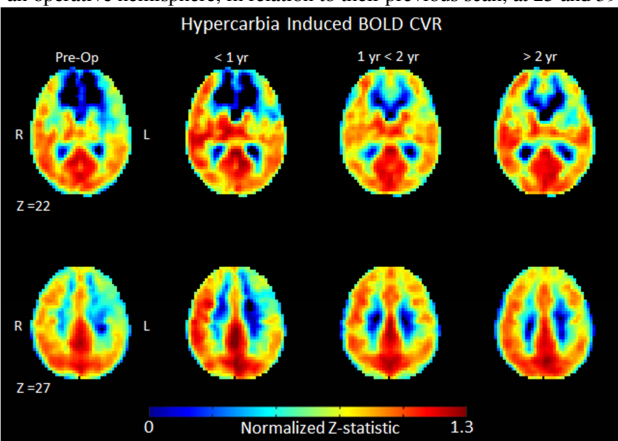


Fig.3. Group-averaged BOLD CVR maps (occipital lobe-normalized Z-statistic) sorted by post-op time. Operative hemispheres oriented on radiological left. Two representative slices ($4\times4\times4$ mm³ MNI) are shown for each time period.

Methods: *Experiment.* 71 patients with symptomatic intracranial stenosis, including 29 patients with Moyamoya disease, were scanned at 3T (Philips) over a period of three years as part of an ongoing, prospective trial. All patients provided informed, written consent in accordance with local IRB and HIPAA guidelines. Of the Moyamoya patients, pre- and post-revascularization scans were available on five (1 M / 4 F; age: 36.2 ± 15.4 yrs), with three patients having had two post-revascularization scans (total of three scans). An additional five patients (1 M / 4 F; age: 39.5 ± 5.4 yrs), had no pre-revascularization scan, but at least two post-revascularization scans. To assess CVR, patients were given a hypercarbic hyperoxic (carbogen; 5% CO₂ / 95% O₂) gas challenge (3min x 2) while BOLD-weighted MRI data (TR/TE=2000/35 ms; spatial resolution = $3\times3\times4$ mm³) were acquired. Carbogen was administered to avoid reductions in the fraction of inspired oxygen, as several patients were hypoxic ($Y_a<0.94$). Physiological parameters, including EtCO₂, Y_a, heart rate, and respiratory rate were monitored by a respiratory therapist. *Analysis.* BOLD data were corrected for baseline drift and motion, then co-registered to native (T₁) and standard (MNI, 4mm) space. Z-statistics, a surrogate marker of CVR, were calculated and normalized by the mean Z-statistic value in the occipital lobe, as

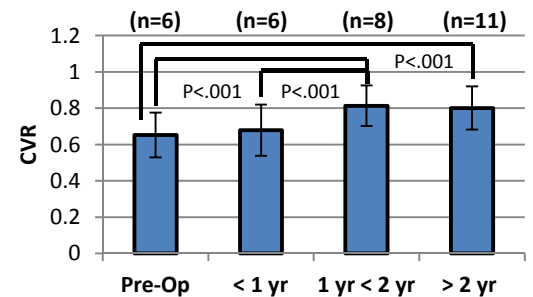


Fig.2. CVR, as measured by occipital lobe-normalized BOLD Z-statistics, for 13 hemispheres with at least 2 scans, demonstrating gradual improvement in CVR for at least two years post-op.

Discussion: The primary findings of this study are (i) non-invasive hemodynamic measures of CVR can be performed routinely in

hypoxic patients with symptomatic ischemic cerebrovascular disease to evaluate disease progression and (ii) on average, Moyamoya patients continue to experience increased CVR in the operative hemisphere for at least two years following revascularization surgery. It is well-established that direct and indirect surgical revascularization lead to symptom improvement and increased perfusion in Moyamoya patients^{2,3}. However, a timeframe delineating expected improvements in CVR has not yet been described. Our data suggest that in patients imaged pre- and post-op, CVR increases were still evident at an average of 17 months post-op. These results support our primary findings, based on a total of 10 patients (13 operative hemispheres), indicating gradual improvements in operative hemisphere CVR following surgery for at least two years.

Conclusion: Longitudinal BOLD-based CVR monitoring of ischemic Moyamoya patients was achieved using carbogen administration with no adverse events, and results indicate CVR continues to increase in operative hemispheres for at least two years post-operatively.

References: 1. Donahue, MJ, et al. JMRI. 2013; 38(5): 1129-1139. 2. Guzman, R, et al. J Neurosurg. 2009; 111(5): 927-935. 3. Karasawa, J et al. J. Neurosurg. 1978; 49(5): 679-688.