

WHITE MATTER IMPAIRMENT IN DEPRESSION AND HYPERTENSION: A DIFFUSION KURTOSIS IMAGING STUDY AT 3-T MR

Xiangzhu Zeng¹, Huishu Yuan¹, Ying Liu¹, Zheng Wang¹, and Han Zhang²

¹Dept of Radiology, Peking University Third Hospital, Beijing, Beijing, China, ²Dept of the consultation liaison, Peking University Mental Health Institute, Beijing, Beijing, China

Purpose:

Depression is a common psychiatric disorder and the prevalence of clinically significant depressive syndromes are on the rise. Some patients with comorbid hypertension in depression have more severe syndromes than those with only depression, but the mechanism is still uncertain. Diffusion Kurtosis imaging (DKI) is a noninvasive method by using a non-Gaussian model to probe restricted water diffusion in biological tissues and detect microstructure impairments in vivo^[1]. Mean kurtosis(MK) is a critical parameter of DKI and reveals the white matter damage accurately^[2]. The aim of this study is to investigate the differences of white matter impairment between depression and comorbid hypertension in depression.

Material and Method:

Patients with depression (n=15, 3men and 12women, age range 34-68 years, mean age 57.3 ± 8.93 years), comorbid hypertension in depression (n=22, 2men and 20women, age range 42-73 years, mean age 61.2 ± 6.82 years), hypertension(n=28, 7men and 21women, age range 40-78 years, mean age 59.2 ± 7.53 years) compared with age- and sex-matched healthy control subjects(HC, n=20, 4men and 16women, age range 33-68 years, mean age 56.3 ± 8.52 years)were recruited. All MRI examinations were performed using a 3.0T scanner. DKI scanning were conducted with 45 images acquired on a GE750 3T scanner. The acquisition parameters were as following: TR=8000ms; TE= 93.5ms; slice thickness 3 mm; field of view (FOV) 24x24 cm; matrix 128x128, voxel size= $2 \times 2 \times 4$ mm³, diffusion directions 31, b value 0,1000 s/mm²,2000 s/mm², scan time 8min40sec. Voxel-based analysis was used to analyze DKI data(SPM8, DKE). MK in patients with depression, comorbid hypertension in depression and hypertension were compared with HC respectively.

Results:

Compared to HC, we found significant decrease in Mean Kurtosis (MK) of patients with depression (Pcorrected <0.05, FWEp=26.52; cluster size >50) in the right cerebellum, left thalamus and right putamen (Fig 1, 2); Compared to HC, there are more cerebral regions of individuals with comorbid hypertension in depression involved according to the significant decrease in MK (Pcorrected <0.05, FWEp=26.52; cluster size >50), including bilateral cerebellum, bilateral temporal gyri, bilateral fusiform gyri, bilateral parahippocampal gyri, bilateral precuneus, right middle cingulate gyrus, left posterior cingulate gyrus, left superior frontal gyrus, right hippocampus, right lingual gyrus, right putamen and pallidum, left thalamus (Fig 3,4) (Table 1). There is no significant decreased areas in hypertension group compared to HC (Pcorrected <0.05, FWEp=26.52; cluster size >50).

Conclusions:

Our results reveal underlying extensive white matter impairments in patients with depression and hypertension. As temporal lobe, precuneus, cingulate gyrus, parahippocampal gyri and hippocampus are involved, the patients with comorbid hypertension in depression may have more cognitive impairment. The different patterns of decrease in MK suggest hypertension may play a synergistic action in the progress of depression. As a potential biomarker, DKI could differentiate the patients from the healthy.

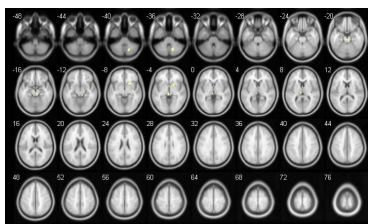


Fig.1

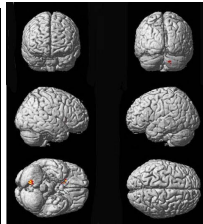


Fig.2

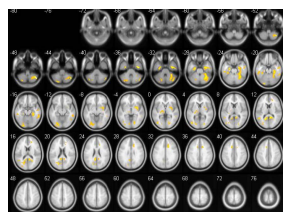


Fig.3

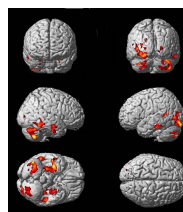


Fig.4

Cerebral areas	MMNI (peak point)			voxel
	X	Y	Z	
Bilateral cerebellum	44	-62	-48	1573
Bilateral temporal gyri	60	-44	-18	447
Left posterior cingulate gyrus	-10	-48	22	104
Right middle cingulate gyrus	14	18	32	91
Left superior frontal gyrus	-17	16	42	51
Bilateral fusiform	38	-8	-36	403
Right hippocampus	26	-8	-36	62
Bilateral precuneus	10	-46	10	232
Bilateral lingual gyri	18	-80	-4	257
Bilateral parahippocampal gyri	34	-10	-30	342
Right putamen and pallidum	34	0	-6	308
Left thalamus	-12	-20	0	97

Table.1

Fig1-2: Depression vs Health control.

Fig3-4: Comorbid hypertension in depression vs Health control.

Table1. Cerebral areas involved in comorbid hypertension in depression group compared to health control group.

References:

- [1] Jensen JH, Helpern JA. MRI Quantification of Non-Gaussian Water Diffusion by Kurtosis Analysis. NMR Biomed, 2010, 23(7):698-710.
- [2] Maria F. Falangola, Jens H. Jensen, Ali Tabesh, et al. Non-Gaussian diffusion MRI assessment of brain microstructure in mild cognitive impairment and Alzheimer's disease. Magnetic Resonance Imaging, 31 (2013) 840 - 846.