

## Regional EEG Theta Increase enhances fMRI activity findings in a simultaneous EEG/fMRI study during Auditory Hallucinations in Chronic Schizophrenic Patients

Beatriz Dionisio<sup>1,2</sup>, Gracián García Martí<sup>1,3</sup>, Conrado J Calvo<sup>4</sup>, Nicolás Peñaranda<sup>2</sup>, Ana Beatriz Solana<sup>5</sup>, J. A. Hernández-Tamamés<sup>5</sup>, Luis Martí-Bonmatí<sup>3</sup>, and Julio Sanjuán<sup>1,2</sup>

<sup>1</sup>University of Valencia, CIBERSAM, Valencia, Valencia, Spain, <sup>2</sup>Instituto de Investigación Sanitaria, INCLIVA, Valencia, Valencia, Spain, <sup>3</sup>Servicio de Radiología, Hospital Quirón de Valencia, Valencia, Spain, <sup>4</sup>Instituto ITACA-Bio. Universitat Politècnica de València, Grupo Electrofisiología y Bioingeniería (GEB), Valencia, Spain, <sup>5</sup>Fundación CIEN, Fundación Reina Sofía, Madrid, Spain

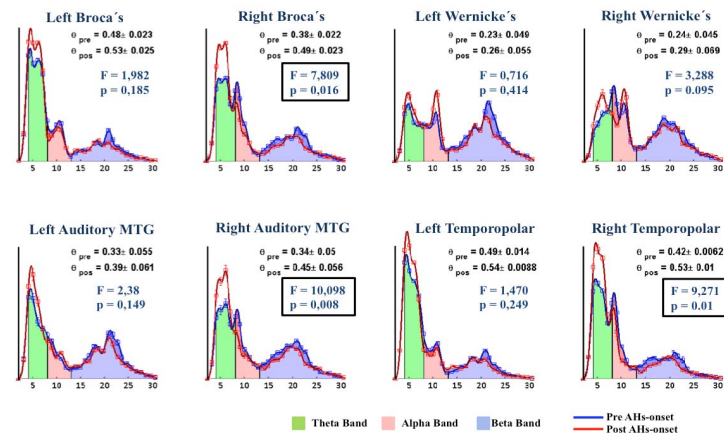
**Introduction:** Auditory hallucinations (AHs), as perceptions of voices in absence of external stimuli, are a core symptom of schizophrenia. The pathophysiology of AHs remains poorly understood due to the complexity to capture the spontaneous episodes and the lack of knowledge about its neuronal dynamics. Neuroimaging techniques have proved to be a powerful tool to explore AHs spatiotemporal pattern<sup>1</sup>. Both electrophysiological studies<sup>2,3</sup>, looking into specific band activity changes over the course of AHs, and fMRI studies<sup>4</sup>, attempting to find hemodynamic activations in involved areas, have shown inconsistent findings. In this study, by using simultaneous EEG/fMRI techniques, we aimed to identify power spectral differences of brain waves, linking the regional findings to intrinsic hemodynamic activations leading to AHs in chronic patients.

**Methods Subjects:** 6 chronic schizophrenic (DSM-IV) patients were selected for this study. All had persistent auditory hallucinations and heard voices during simultaneous EEG/fMRI experiments. Patients were clinically assessed with PSYRATS and PANSS scales, and gave written informed consent. **Experiment and Data Acquisition:** Patients were instructed to press a button at the beginning ('on') and at the end ('off') of any AH event with their right hand. *i) EEG data* were recorded using a Brain Products MR-compatible EEG system with 64 electrodes (10-20 system). *ii) fMRI data* were collected using a Philips Achieva 3.0 T MR scanner with an EPI sequence lasting 5.3 min (160 volumes, TR =2000ms). An optimal synchronization scheme between EEG and MR systems was used to improve the EEG artefact removal. **Data Preprocessing:** *i) EEG Data:* Brain Vision Analyzer 2.0 was used to remove MR scanner artefacts in the EEG. *ii) fMRI data:* Standard preprocessing was applied to MR images using SPM8 (realignment, slice timing correction, normalisation and spatial smoothing (FWHM=8mm)). **Data Analysis and Statistics:** *i) EEG Data:* A digital band-pass filter was applied to the band of interest (4 - 30 Hz) and pre/post AH-onset 4s-segments were extracted. Artefact-free segments were selected by visual inspection. Welch method was used to obtain the power spectral density from three frequency bands— theta (4-7.9 Hz), alpha (8-12.9Hz) and beta (13-30 Hz) – for each segment. Normalized values against total power density were calculated across episodes, averaging electrodes corresponding to eight regions of interest: Inferior-Middle Temporal, Temporopolar, Broca's, Wernicke's (and their right homologous). One-factor ANOVA statistic test was used for EEG pre/post regional comparisons, using SSPS (SSPS Inc.). *ii) fMRI data:* Three GLM designs per fMRI series were computed (SPM8), one using the AH-onsets and two other with pre/post time shifts (-2s, +2s), as events convolved with the canonical HRF. As result, three contrast maps were obtained for each patient, considered significant for a  $p < 0.001$  (uncorrected, 100 voxels).

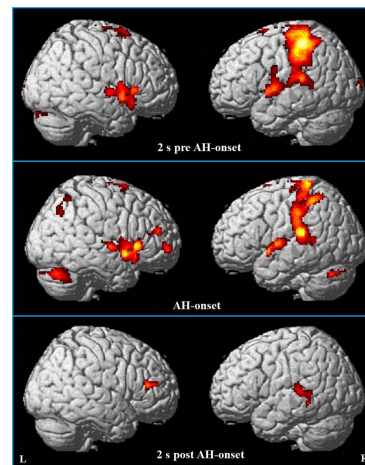
**Results:** EEG analysis revealed consistent spectral profiles for each region across subjects. However, theta periodic components increased activity after the hallucinatory onset and it was reflected by theta-band power changes for all individual patients, meanwhile, alpha and beta activity slightly decreased or remained stable. Preliminary results with spectral normalized averaged pre/post profiles are shown below for one patient (Figure 1), highlighting intra-regional pre/post comparisons with a significant theta increase in right auditory and language cortical areas. Interestingly, these changes were located in heterogeneous brain regions across subjects, but were consistently associated to significant fMRI activated areas in each case. fMRI results, after pre/onset/pos time series regression for the same patient showed correlation with EEG counterparts identifying hemodynamic activity in temporal, Broca's and Wernicke's areas (Figure 2). Additionally, it was predominant before the AHs-onset and just remained language related areas activations.

**Conclusion:** Our results suggest that simultaneous EEG/fMRI seems to be a promising technique for thorough investigation on AHs neural spatiotemporal mechanisms alleviating technical limitations. We have demonstrated that both modalities are correlated during the spontaneous AHs, with specific regional increase in theta-band EEG activity and associated hemodynamic activations in auditory and language cortical areas. These findings support the hypothesis that AHs are generated by auditory and language functional disruptions. However, the experiment presented has to be carried out with more patients in order to corroborate our results and to avoid confounding variables of symptomatic heterogeneity.

**References:** 1. Allen F et al, *Neuroscience and Biobehavioral Reviews* 2008, 32:175–191; 2. Ford J. et al, *Schizophrenia Bulletin* (2012) 38 (4): 715-723. 3. Ishii R et al, *Neuroreport* 2000, 11:3283–3287; 4. McGuire PK et al *Lancet* 1993, 342: 703–706.



**Figure 1.** Spectral normalized pre (blue line)/post (red line) AH-onset EEG segments for target brain regions analyzed (8 ROIs) in one patient. Spectral bands of interest are colour coded and error bars represent STE. Noticeable exists a significant theta band increase after the AH-onset, statistically significant in right auditory and language (Broca's) areas (one-factor ANOVA  $p < 0.01$ ).



**Figure 2.** Most significant ( $p < 0.001$ ) activated voxels 2s prior the hallucinations (top), during the onset (middle) and 2 seconds once indicated (down). Activity in auditory areas is predominant before AH-onset and remained in language related areas (Broca's and Wernicke's).