

Correlation of magnetization transfer (MT) and diffusion MRI in sporadic Creutzfeldt-Jacob disease

Gunther Helms¹, Markus Matros², Kai Kallenberg³, Niels K Focke⁴, Inga Zerr⁵, Walter J Schulz-Schaeffer⁶, and Peter Dechent¹

¹Cognitive Neurology, Göttingen University Medical Center, Göttingen, Germany, ²Imaging Diagnostics and Interventional Radiology, Klinikum Wolfsburg, Wolfsburg, Germany, ³Neuroradiology, Göttingen University Medical Center, Göttingen, Germany, ⁴Neurology, Tübingen University Hospital, Tübingen, Germany, ⁵Neurology, Göttingen University Medical Center, Göttingen, Germany, ⁶Neuropathology, Göttingen University Medical Center, Göttingen, Germany

Targeted Audience

Neuroradiologists

Purpose

Reduced diffusivity is the diagnostic hallmark of sporadic Creutzfeldt-Jacob disease (sCJD), which is not reliably detected by conventional MRI. The relative influence of gliosis, amyloid plaques, and encapsulated microcysts on the self-diffusion of water remain unclear^{1,2,3}. The MT saturation is a novel semi-quantitative parameter for magnetization transfer (MT)⁴. These high-resolution MT maps provide a high intrinsic contrast of brain tissue, in particular within deep gray matter (GM) structures⁵. This pilot study aimed at whether this novel MT parameter is sensitive to tissue degeneration in sCJD.

Methods

Five patients with definite or probable sCJD (47 to 71 years, 1 male) at different stages of the disease and 10 healthy controls (46 to 81 years, 5 male) were examined in a 3T MR system (Siemens TIM TRIO) using an 8 channel head receive array.

First, a T1-w anatomical dataset at 1 mm was acquired (3D MP-RAGE). MT saturation mapping was performed in 8.5 mins⁴ by three 3D FLASH acquisitions (1.25 mm, 128 sagittal partitions, TE = 4.92 ms, 200 Hz/pixel) with T1-w ($\alpha/TR=15^\circ/11ms$), PD-w (proton density, $5^\circ/25ms$), and MT-w ($5^\circ/25ms$) with a 12.8 ms Gaussian MT pulse, 540° , 2.2kHz off resonance. Transversal maps of the mean diffusivity (MD) (19 EPI slices at $b = 0, 0.5, 1 ms/\mu m^2$, TE = 91 ms, 5+1.5 mm thickness, 1.8 mm resolution in-plane) were measured in patients and 6 additional controls. Whole-brain maps of the MT saturation were calculated using FSL 4.1. Regions-of-interest (ROIs) in the caudate head, anterior putamen, and pulvinar of the thalamus were evaluated bilaterally. The amygdala served as control region. Finally MT maps were registered to the MD maps after 2x2x6-fold upsampling of the low resolution pixels (Fig. 1). Corresponding ROIs were selected within a single 2D slice accounting for distortion in the EPI phase direction.

Results

In sCJD, the MT saturation was significantly reduced in the caudate head (1 patient excluded due to atrophy) and putamen indicated an increased water content, but not in the pulvinar and the amygdala (see boxplots in Fig. 2). In caudate and putamen, a significant correlation indicated that hindered diffusion is associated with increased water content (black squares in the scatterplots in Fig. 3.). Here, controls showed a lower variance in MD and no co-variance. The inverse correlation observed in the pulvinar related hindered diffusion to a higher macromolecular content, e.g. due to different axonal content.

Discussion

While standard MRI does not reliably depict tissue alterations in sCJD, detection is based on microstructural properties of tissue, commonly diffusion. This study relates low diffusivity to reduced MT, consistent with the dominating influence of encapsulated microcysts in spongiform degeneration but not of amyloid plaques. This in vivo finding is still pending histological confirmation. Sensitivity of MT is explained partly by the enhanced contrast within the deep brain⁵ and the correction for T1 and radiofrequency inhomogeneity. MT mapping at 1mm is clinically feasible (5) and may give access to cortical GM alterations. Distortion-free diffusion imaging using STEAM⁶ will improve the spatial congruence for an improved comparison.

Figure 1: MT and MD map in histologically confirmed sCJD

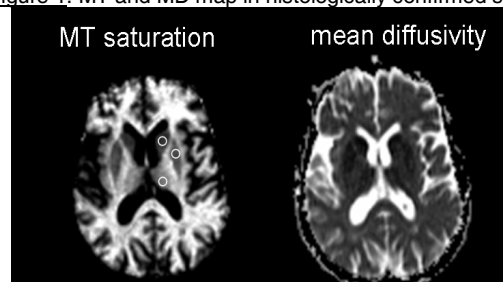


Figure 2: Boxplots of MT saturation in selected GM areas. controls = grey, sCJD = white. Outliers in amygdala are due to motion artefacts.

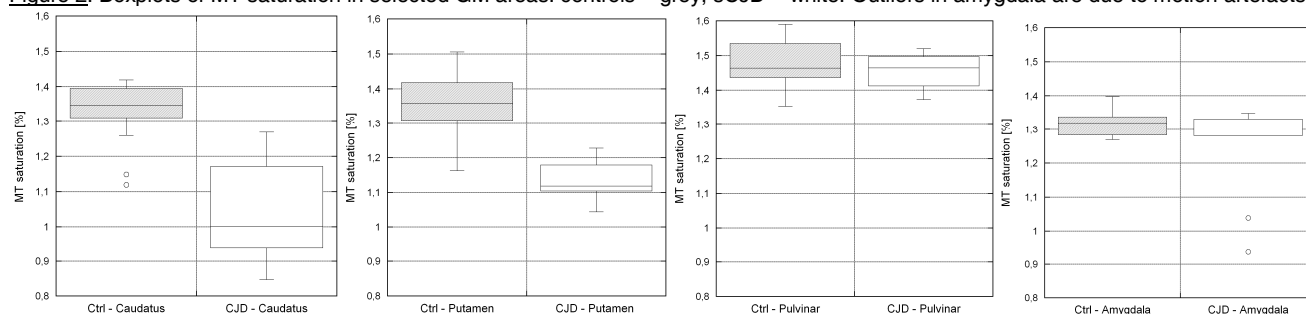
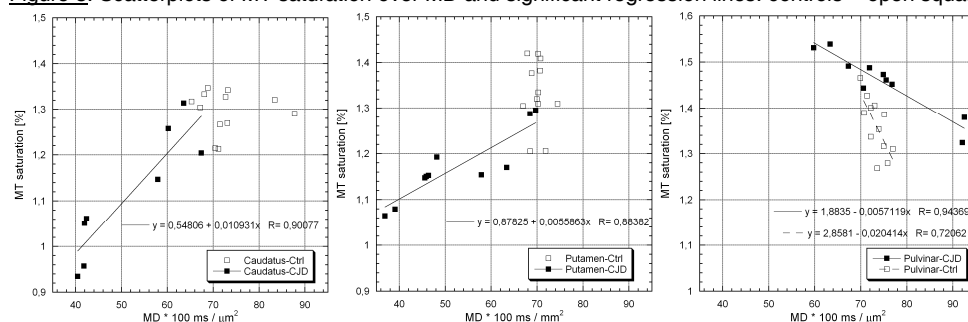


Figure 3: Scatterplots of MT saturation over MD and significant regression lines. controls = open squares: cCJD = solid squares



References

1. Manners DN et al. *Neurology* 72(16) 1425-31, 2009
2. DeArmond SJ et al. *Alzheimer Dis Assoc Disord* 23 82-7, 2009.
3. Halperin J et al. *Arch Neurol* 59 128-34, 2010
4. Helms G et al. *MRM* 60(6) 1396-407, 2008.
5. Helms G et al. *NeuroImage* 47(1) 194-8, 2009.
6. Nolte UG et al. *MRM* 44(5) 731-36, 2000.