

Different patterns of White matter and Grey matter involvement account for Behavioural and Psychological symptoms in Alzheimer's disease

Elena Makovac¹, Laura Serra¹, Barbara Spanò¹, Giovanni Giulietti¹, Mario Torso¹, Mara Cercignani^{1,2}, Carlo Caltagirone^{3,4}, and Marco Bozzali⁵

¹Neuroimaging Laboratory, IRCCS Santa Lucia Foundation, Rome, Italy, ²Clinical Imaging Sciences Centre, Brighton and Sussex Medical School, United Kingdom, ³Department of Clinical and Behavioural Neurology, IRCCS Santa Lucia Foundation, Rome, Italy, ⁴University of Rome 'Tor Vergata', Rome, Italy, ⁵Neuroimaging Laboratory, IRCCS Santa Lucia Foundation, Italy

PURPOSE: Behavioral disorders and psychological symptoms (BPSD) in Alzheimer's Disease (AD) are known to correlate with grey matter (GM) atrophy (1) and, as shown recently, also with white matter (WM) damage (2). WM damage and its relationship with GM atrophy are reported in AD (3), reinforcing the interpretation of the AD pathology in light of a *disconnection syndrome* (4). Whether this disconnection might account also for different BPSD observable in AD remains uncertain. Here, we tested the hypothesis of different patterns of association between WM damage of the Corpus Callosum (CC) and GM atrophy in AD patients exhibiting one of the following BPSD clusters (5): Mood (i.e. anxiety and depression; AD_{mood}), Frontal (i.e. disinhibition and elation; AD_{frontal}), Psychotic (delusions and hallucinations; AD_{psychotic}) or Apathy (AD_{apathetic}) related symptoms, in comparison to AD patients without BPSD (AD_{noBPSD}).

MATERIAL AND METHODS: We enrolled 60 AD patients and 26 healthy controls (HC). All subjects underwent extensive neuropsychological assessments (including the Neuropsychiatric Inventory for AD patients) and MR scanning at 3T (Magnetom Allegra, Siemens), including the following acquisitions: Dual-echo turbo spin echo (TSE) (repetition time [TR]= 6,190msec, echo time [TE]= 12/109 msec); (2) fast-FLAIR (TR= 8,170 msec, TE= 96 msec, TI= 2,100 msec); (3) 3D Modified-Driven-Equilibrium-Fourier-Transform (MDEFT) scan (TR=1338 ms, TE=2.4 ms, Matrix=256x224x176, in-plane FOV=250x250 mm², slice thickness=1 mm). DTI data acquisition: dMRI data were obtained along 61 non-collinear directions, with b values of 0 and 1000 s.mm⁻² on a 3 T Siemens Allegra scanner resulting in 45 contiguous slices volumes with a 2.3 mm isotropic reconstructed voxel size. **DTI processing:** Data were corrected for head movements and eddy currents using non-linear registration. Then fractional anisotropy (FA) and Mean diffusivity (MD) were computed from the diffusion tensor (DT) fitted with weighted linear least-square using Camino (6). **Tractography:** The Corpus Callosum was reconstructed with multi-fiber probabilistic tractography carried out using 10000 iterations of the probabilistic Index of Connectivity (PICO) algorithm (7) applied to fiber orientation distribution functions estimated with PAS MRI (8). Five principal parts of the CC were reconstructed separately, following the classification by Hofer et al. (9; see Fig1). GM analysis: voxel based morphometry (VBM) based on a two-sample T-test was applied to cortical GM maps warped to MNI space (with SPM 8). Age, education and MMSE scores were introduced as variables of no interest.

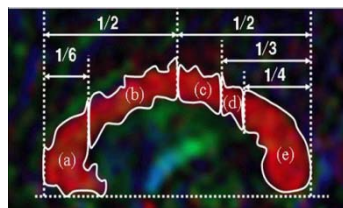


Fig. 1 Delineation of the 5 regions of interest of the CC: (a) genu; (b) anterior midbody, (c) posterior midbody (d) isthmus (e) splenium (7).

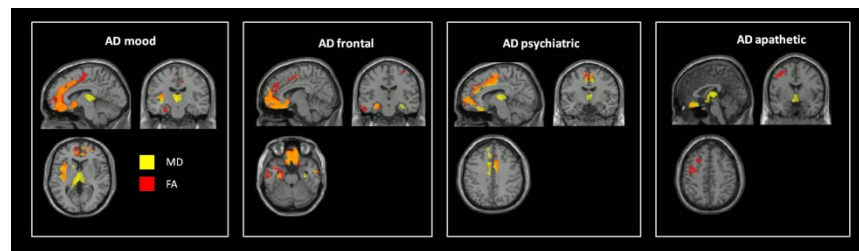


Fig. 2 Different patterns of correlation between microstructural WM damage of the genu and anterior midbody of the CC and GM atrophy in patients exhibiting one of the four clusters of NPI symptoms.

RESULTS: DTI analysis. AD patients showed increased MD values and decreased FA values in all five CC parts in comparison to HC ($p < 0.05$, Bonferroni corrected). **WM and GM correlation analysis.** Correlation analysis in HC and AD_{noBPSD} patients showed no association between MD/FA of the CC and GM when controlling for the overall cognitive level. Conversely, a negative correlation was obtained between MD of the Genu and the anterior Body of then CC and volume of, respectively, left insula, frontal medial cortex (FMC) and thalamus ($p < 0.005$, FWE) in AD_{mood}; Frontal medial cortex (FMC) and parahippocampal gyrus ($p < 0.005$, FWE Fig.2, yellow areas) in AD_{frontal} patients; paracingulate gyrus and thalamus in AD_{psychiatric}. FA values followed the same pattern of correlation although to a lesser extent (Fig.2, red areas), whereas no correlation was evident with WM metrics in the Isthmus, Splenium and posterior Body of CC and the GM volumes in the three groups of patients.

DISCUSSION: Our study brings to light the strict relationship between WM alterations in different parts of the CC and GM atrophy in AD patients exhibiting four main BPSD: mood alterations, frontal deficits, psychosis and apathy. Here we show that the relationship between WM tract changes and atrophy of specific GM areas is mediated by the presence of specific BPSD symptoms in patients with AD. Therefore, such symptoms are likely to be caused by characteristic patterns of neurodegeneration, rather than being a reactive response to accumulation of cognitive disabilities, and should therefore be regarded as potential markers of diagnostic and prognostic value in AD.

REFERENCES [1] Serra, L. et al. (2010). J. Alzheimers Dis. 21, 627–639. [2] Hahn, C. et al. (2013). PLoS One. 8(1):e53493. [3] Agosta, F. et al. (2011). Radiology, 258 (3), 853–863. [4] Bozzali M. et al., (2011) Current Medicinal Chemistry, 18, 2452–2458 [5] Frisoni, GB et al. (1999), Dement Geriatr Cogn Disord 10, 130–138. [6] Cook, PA. et al., (2005) An automated approach to connectivity-based partitioning of brain structures. In: Proc. MICCAI. [7] Parker et al. (2003), J Magn Reson Imaging [8] Jansons KM, Alexander DC (2003) Inf Process Med Imaging;18:672–83 [9] Hofer S., Frahm J. (2006). Neuroimage 32, 989–994.