

Effects of Residual Oxygen Molecule on BOLD signal: MRI Study Using Spontaneously Breathing Brain Stroke model

Ji-Yeon Suh¹, YoungKyu Song¹, Jeong Kon Kim^{1,2}, Young Ro Kim³, and Gyunggoo Cho¹

¹Magnetic Resonance Research, Korea Basic Science Institute, Cheongwon, Chungbuk, Korea, ²Asan Medical Center, University of Ulsan College of Medicine, Seoul, Korea, ³Athinoula A. Martinos Center for Biomedical Imaging, Massachusetts General Hospital, Charlestown, United States

INTRODUCTION: BOLD (blood oxygen-level dependent) contrast is recognized as a signal intensity increase due to the decreasing of magnetic susceptibility effect when a paramagnetic deoxyHb is converted to diamagnetic oxyHb. However, it has been frequently observed BOLD signal decreases in hyperoxia despite reduced deoxyHb concentration by pure oxygen inhalation. This indicates that oxygen-induced magnetic susceptibility effect can influence on BOLD signal contrast in oxygen-rich condition although a paramagnetic effect of oxygen is weaker than that of deoxyHb. Here, we aimed to evaluate the paramagnetic effects of oxygen molecule on MR BOLD signal and the PET estimated FDG (fluorodeoxyglucose) uptakes, a glucose marker for oxygen metabolism, in brain stroke model with both normoxia (FiO₂, 21%) and hyperoxia (FiO₂, 100%) inhalations to suggest that oxygen molecule itself could be a useful contrast agent in company with deoxyHb.

MATERIALS & METHODS: MR experiments were performed on a 4.7T magnet system (BioSpec, Bruker) with the spontaneous breathing rats (n=8) following 1, 7, and 14 days after 1-hour occluded middle cerebral artery occlusion surgery for the measurements of R1 (1/T1), R2 (1/T2), R2*(1/R2*). Additional T2- and T2*-weighted images were acquired after administration of superparamagnetic iron oxide nanoparticles (SPION) to obtain CBV (R2*_{postSPION}-R2*_{preSPION}), MVV (R2*_{postSPION}-R2*_{preSPION}) and VSI (CBV/MVV). Region of interests (ROI) for the stroke hemisphere were defined according to the decrease of apparent diffusion coefficient (ADC). Stroke core and peri ROIs were drawn at the area where the ADC were below mean (cortex of non-ischemic hemisphere) minus 2 s.d. and where the ADC were between mean-2s.d ~ mean-sd, respectively.

RESULTS & DISCUSSION: With normoxia respiration, ipsilesional (stroke-affected) hemisphere showed lower R1 compared to the mirror area of the opposite hemispheres (contralateral), whereas both hemispheres had similar R1 values with hyperoxia inhalation, which results in larger deltaR1 (R1_{oxygen}-R1_{roomair}) distribution in stroke core area (Fig. 1). No meaningful R2 and R2* values were shown between ipsilesional and contralateral, and between normoxia and hyperoxia. However, CBV differences were significantly different not only between normoxia and hyperoxia but also between ipsilesional and contralateral hemispheres. In addition, MVV values in ipsilesional hemisphere were considerably lower compared to those in contralateral hemispheres (Fig. 2). Hemispherically decreased FDG uptakes at 1 day were showed and which was recovered over time at 7 and 14 day follow ups (Fig. 3). These results suggest that the direct BOLD signal change is related to the blood volume. Furthermore, given that different signal changes in stroke-affected tissues which do not need oxygen consumptions for the recruitments of oxygen metabolic pathways may be induced by higher amounts of residual oxygen molecules, different levels of residual oxygen molecules can be a significant factor that determines the BOLD signal changes.

REFERENCE [1] Dennie, J., MRM, 1998 [2] Christen T. et al., AJAR, 2012

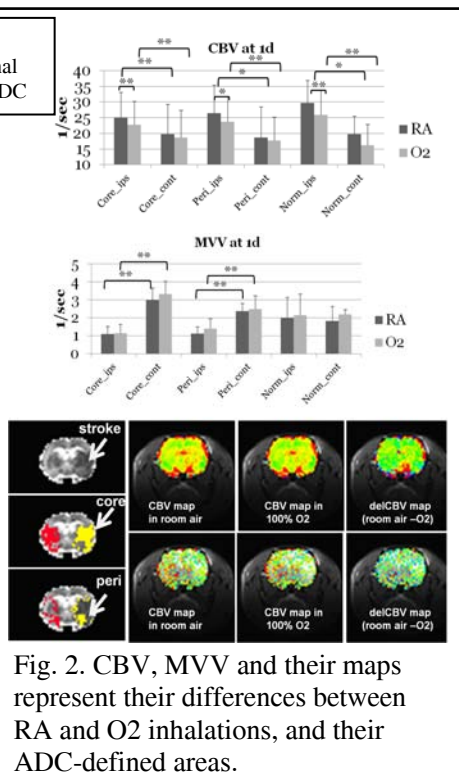
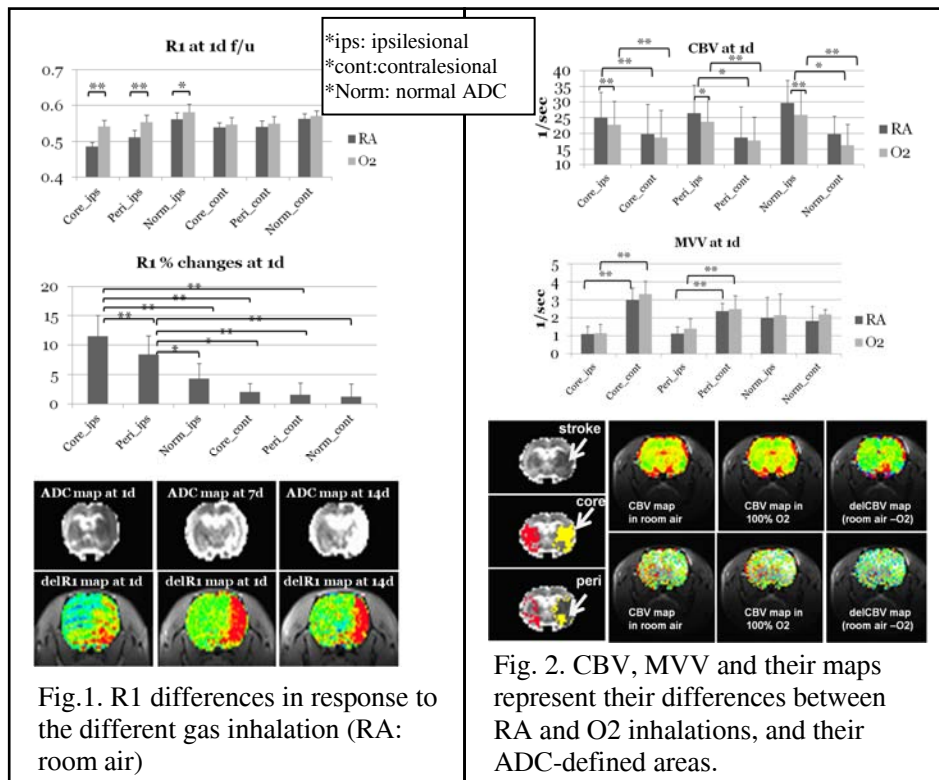


Figure 3 shows representative images for decreased FDG uptake in whole ipsilesional hemisphere. The figure contains three brain maps labeled '1d FDG uptake', '7d FDG uptake', and '14d FDG uptake'. The first map shows 'Underlay: T2 (MRI)' and 'Overlay: FDG uptake (PET)'. The second and third maps show '1d FDG uptake', '7d FDG uptake', and '14d FDG uptake' respectively.

Fig. 1. R1 differences in response to the different gas inhalation (RA: room air)

Fig. 2. CBV, MVV and their maps represent their differences between RA and O2 inhalations, and their ADC-defined areas.

Fig. 3. Representative images for decreased FDG uptake in whole ipsilesional hemisphere