

Combination normobaric oxygen and methylene blue treatment delays the progression of ischemic penumbra into infarct and promotes behavioral recovery

Pavel Rodriguez^{1,2}, Jiang Zhao², Brian Milman³, Lora Talley Watts², and Timothy Q. Duong²

¹Department of Radiology, University of Texas Health Science Center at San Antonio, San Antonio, Texas, United States, ²Research Imaging Institute, University of Texas Health Science Center at San Antonio, San Antonio, Texas, United States, ³School of Medicine, University of Texas Health Science Center at San Antonio, Texas, United States

Target Audience Researcher in stroke and neuroprotection

INTRODUCTION We previously reported that methylene blue (MB) – an energy enhancing and antioxidant – reduced infarct volume in 60-mins and permanent MCAO in rats.¹ We and others have also previously reported that normobaric oxygen (NBO) treatment also reduces infarct volume.^{2,3} The goal of this study was to evaluate the combination therapy of MB and NBO treatment in ischemic stroke. We hypothesized that MB+NBO treatment delays infarct growth and salvages more tissue than NBO alone in a 60-min MCAO model in rats.

METHODS Male SD rats (250-350g, N=13) were subjected to 60-min MCAO. Two treatment groups were studied using a randomized and double-blinded experimental design: NBO+vehicle (n=7) and NBO+MB (n=6). MB or vehicle was administered at 0.5hr, 1.2hrs (immediately post-reperfusion), 2 days, 7 days, and 14 days after stroke (1 mg/kg i.p. at 2, 7 and 14days). Each 1mg/kg MB bolus was administered over 30min before and after reperfusion via i.v. on day 0. NBO (2.5L/min) was given from 0.5 to 3hr after stroke. Oximetry and rectal temperature were maintained within normal physiological ranges. Behavioral testing was also acquired at 2, 7, 14 and 28 days after stroke.

A pretreatment MRI data set was acquired 25-30min after stroke. ADC and CBF MRI measurements were acquired from 15 mins to 3 hrs, again on 2, 7, 14 and 28 days after stroke on a 7-T. Based on 30-min ADC and CBF maps were classified.

T-test was used for comparison between initial lesion and final infarct or between treated and control groups. Edema correction was applied for the day 2 T2 measurements. A p value of 0.05 was taken to be statistically significant. Data showed in figures and texts are mean \pm SEM.

RESULTS AND DISCUSSION Figure 1 shows representative CBF, ADC and T2 images of the NBO + vehicle and NBO + MB treatment groups at different time points. The initial (30min) CBF lesion volume was $328.1 \pm 16.1 \text{ mm}^3$ for NBO+vehicle and $331.3 \pm 16.7 \text{ mm}^3$ for NBO+MB. Reperfusion was successful in all animals as indicated by restoration of CBF. Figure 2 shows the group-averaged lesion volumes defined by abnormal CBF, ADC and T2. ADC and CBF initial lesion volumes at 30 min post MCAO were not statistically different among groups ($P=0.7$), confirming the starting lesion before treatment were similar among groups. For both groups, ADC defined lesion decreased after reperfusion and remained smaller than the initial 30 mins time points. The ADC defined lesion volume of the MB+NBO group was smaller than that of NBO + vehicle group prior to reperfusion but not statistically significant ($p=0.08$). The T2 infarct volumes of the NBO+MB group were smaller than those of the NBO+vehicle group for Day 2, 7, 14 and 28 ($P<0.05$).

Figure 3 shows the percentage of right forepaw asymmetry in the cylinder test. Day 2 could not get scored due to lack of vertical exploration in most animals at this acute time point. There is a statistically significant difference in asymmetric use of the ipsilateral forepaw in the NBO+MB group at 28 days. Figure 4 shows the percentage of left forelimb (contralateral to lesion) foot faults at day 2, 7, 14 and 28. Animals with NBO+MB treatment showed less motor behavioral deficits compared to those with NBO+vehicle treatment.

CONCLUSIONS NBO+MB markedly attenuated the progression perfusion diffusion mismatch to infarct at the first hours and reduced infarct volume 2 days after stroke that persisted to day 28. NBO+MB treatment was more effective than NBO+vehicle treatment in reducing infarct volume and motor behavioral deficits. This neuroprotective effect of the combination therapy is consistent with the notion that NBO improves tissue oxygenation and MB is an energy enhancer and antioxidant

REFERENCES (1) Shen et al. PLoSOne 2013 in press. (2) Henninger et al, JCBFM 2007;27:1632. (3) Tiwari et al. ISMRM 2014 submitted.

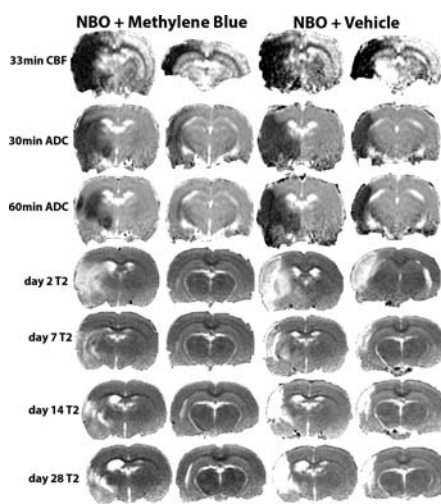


Figure 1. ADC, CBF and T2 measurements for NBO, NBO+Vehicle

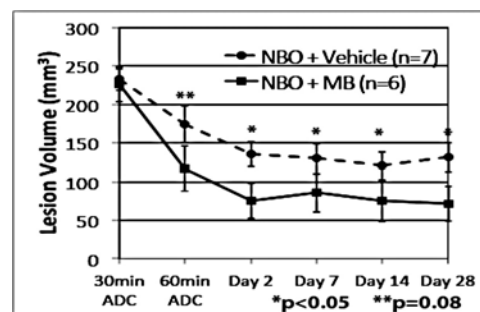


Figure 2. ADC and T2 longitudinal infarction volume measurement in NBO+Vehicle and MB+NBO groups

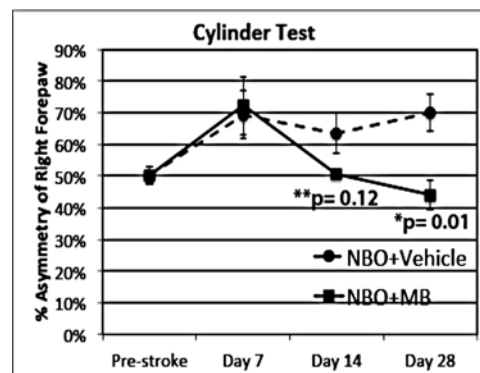


Figure 3. Ipsilateral forepaw overutilization at 7, 14 and 28days decreases faster in the MB+NBO group

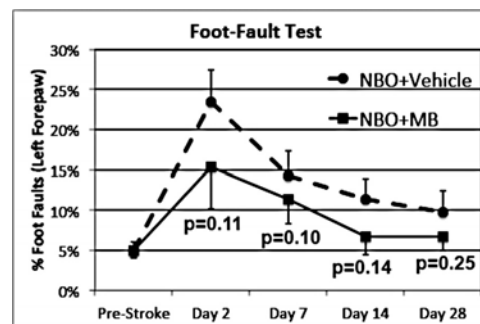


Figure 4. Percentage of left forepaw foot-faults at 2, 7, 14, and 28 days decreases faster in the MB+NBO group