

# Assessment of Bevacizumab Treatment Response in High Grade Gliomas using Intravoxel Incoherent Motion (IVIM): A Comparison with Multi-Echo DSC-MRI

Jack T Skinner<sup>1,2</sup>, Paul L Moots<sup>3</sup>, and C Chad Quarles<sup>1,2</sup>

<sup>1</sup>Radiology and Radiological Sciences, Vanderbilt University Medical Center, Nashville, TN, United States, <sup>2</sup>Institute of Imaging Science, Vanderbilt University Medical Center, Nashville, TN, United States, <sup>3</sup>Neurology, Vanderbilt University Medical Center, Nashville, TN, United States

**TARGET AUDIENCE:** Researchers interested in diffusion MRI methods for quantifying perfusion-based changes in brain tumors.

**PURPOSE:** Perfusion MRI is often used in the evaluation of brain tumors, specifically in studies focusing on tumor treatment. Traditional methods for measuring perfusion rely on the intravenous injection of a contrast agent followed by fast  $T_2^*$  (DSC-MRI) or  $T_{1w}$  (DCE-MRI) measurements. Non-contrast based methods, such as intravoxel incoherent motion (IVIM) MRI, have been shown to be sensitive to perfusion in various biological tissues<sup>1</sup>. Recently, IVIM has been implemented in brain tumor patients, where it has demonstrated use for deciphering tumor grade<sup>2</sup> and distinguishing recurrent tumor from chemoradiotherapy treatment effect<sup>3</sup>. Moreover, the potential for a non-contrast based perfusion-related biomarker in brain tumor patients may be of great value. With regard to longitudinal tumor treatment, however, the effect of commonly used anti-angiogenic drugs (e.g. bevacizumab) on the IVIM signal decay and the associated model parameters is unknown. Therefore, a systematic evaluation and comparison to more traditional perfusion MRI methods (DSC-MRI) in this patient population is needed.

**METHODS:** In this ongoing study, patients with high grade gliomas undergoing bevacizumab therapy ( $n = 4$ ) were imaged at 3T (Philips Achieva) prior to treatment as well as two weeks and four weeks after treatment initiation. IVIM data (DW-SE ssEPI, TR = 6s, TE = 48ms, voxel size =  $2.5 \times 2.5 \times 2.5 \text{ mm}^3$ , NEX = 2, 3 directions,  $b_{\text{val}} = 0, 25, 50, 75, 100, 200, 500, 1000 \text{ s/mm}^2$ ) was acquired prior to contrast agent injection. A single dose of Gd-DTPA (0.1 mmol/kg, 4 mL/s) was then administered, followed by multi-echo DSC-MRI. The multiple b-value data was fit in a least squares manner to a bi-exponential model<sup>4</sup> to extract the perfusion fraction ( $f$ ), pseudo-diffusion coefficient ( $D^*$ ), and tissue diffusion coefficient ( $D$ ). To avoid contributions from CSF and fluid-filled resection cavities, voxels included in the final analysis exhibited  $f < 0.3$ ,  $D < D^* < 100 \cdot 10^{-3} \text{ mm}^2 \cdot \text{s}^{-1}$ , and  $D < 2.0 \cdot 10^{-3} \text{ mm}^2 \cdot \text{s}^{-1}$ . Measures of cerebral blood volume (CBV) and blood flow (CBF) were estimated from the DSC-MRI acquisition<sup>5</sup>.

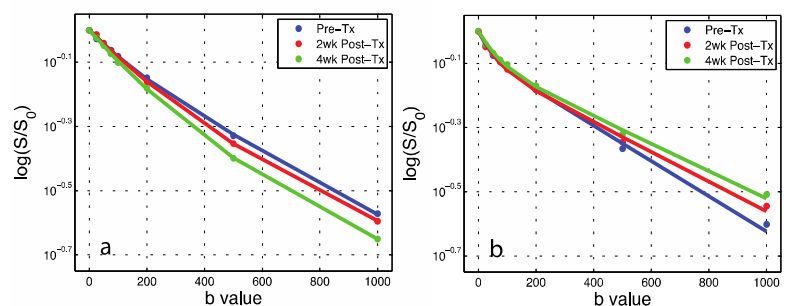


Fig. 1. Pre- and post-treatment IVIM signal decay curves in a) a patient with a favorable response (time to progression (TTP) = >9mo) and b) a patient with a poor response (TTP=2.6mo).

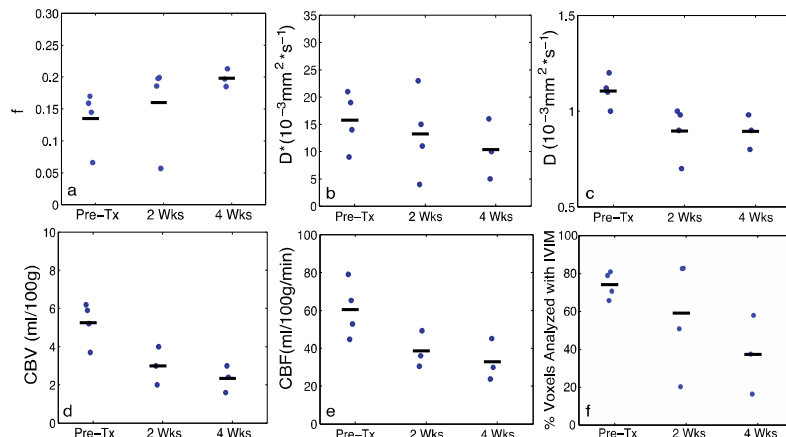


Fig. 2. Mean IVIM (a-c) and (d,e) DSC parameters in tumor at pre- and post-Tx time points. f) % of total tumor voxels incorporated in IVIM analysis.

**RESULTS AND DISCUSSION:** In patients who responded well to treatment (longer TTP), the IVIM decay curves became more monoexponential (Fig. 1). A robust decrease in  $CBV$  and  $CBF$  was observed with treatment, with  $D^*$  trending toward decreased values (Fig. 2). The apparent increase in  $f$  with treatment, contrary to  $CBV$ , may be attributed to limitations of fitting the bi-exponential model as  $D^*$  approaches  $D$ . Additionally, the initial decrease observed in  $D$  is likely due to the resolution of edema. Though the predicative nature of the IVIM model parameters is not yet entirely clear, the decrease in the mean number of voxels suitable for IVIM analysis (Fig 2f), those that meet the criteria above, best reflects the substantial changes in  $CBV$  and  $CBF$  and reinforces differences in the decay curves with treatment.

**CONCLUSION:** IVIM may provide a non-contrast based method for measuring perfusion-related changes in brain tumor patients. Further investigation of the IVIM characteristics, including the change in the number of tumor voxels suitable for analysis (those that exhibit bi-exponential decay), may help validate the efficacy of such a method in monitoring tumor treatment response.

**REFERENCES:** 1. Koh DM, et al. AJR 2011; 196: 1351-1361. 2. Federau C, et al. AJNR 2014; *Early View*. 3. Kim HS, et al. AJNR 2014; *Early View*. 4. Le Bihan D, et al. Radiology 1988; 168:497-505. 5. Ostergaard L, et al. JMRI 2005; 22:710-717.