

Segmentation-based MRI templates for pre-term and full-term newborns

Frédéric Grouiller¹, Laura Gui², Gwénaél Birot³, Alexandra Darqué², Lara Lordier², Petra Hüppi², and François Lazeyras¹

¹Department of Radiology and Medical Informatics, Geneva University Hospital, Geneva, Switzerland, ²Division of Development and Growth, Department of Pediatrics, Geneva University Hospital, Geneva, Switzerland, ³Functional Brain Mapping Laboratory, University of Geneva, Geneva, Switzerland

Target audience: neuroscientists, pediatricians, neonatologists and engineers.

Purpose:

Realistic head models are required to compute EEG source imaging. This is normally performed using well established segmentation methods. In order to apply EEG source imaging in newborn, it is necessary to build specific templates. However, segmentation methods developed for the adult brain are not applicable to the neonatal brain due to differences in tissues properties. The contrast between grey and white matter is inverted and significantly reduced when compared to adults. Therefore, we created segmented templates for preterm and full-term newborns that may be used to build a realistic model for EEG source localization in newborn.

Methods: T1 and T2 structural images of 11 full-term infants (GA 40.4±1.1wks) and 21 premature infants (GA 27.5±1.1wks) were acquired at term-equivalent age (GA 41.1±1.8wks) on a Siemens Trio 3T, with the following parameters: T1: MPRAGE protocol (3D), TE = 2.5 ms, TI = 1100 ms, TR = 2200 ms; T2: turbo spin echo protocol (2D coronal slices), TE = 150 ms, TR = 4600 ms; resolution 0.8x0.8x1.2mm³ for both scans.

After bias field correction and coregistration of the T2 image to the T1 image, we segmented each individual brain using a morphology-driven automatic segmentation developed for the neonatal brain¹. This segmentation produces a labeled image of the individual brain classifying: cortical and subcortical grey matter, white matter, cerebrospinal fluid (CSF), brainstem and cerebellum. The bone and skin were then automatically segmented using unified segmentation in SPM12. An individual mask was created for each tissue. The T2 images were then normalized to a newborn brain template. The normalization transformation was applied to the T1, to the individual labeled segmentation and to each tissue mask.

T1 and T2 templates for preterm and full-term newborn were created by averaging the images of the group. For each tissue, the normalized masks were averaged to obtain tissue probability maps. A labeled segmentation template was built selecting the voxelwise maximum of these tissue probability maps.

Results: We created segmented brain templates for preterm and full-term newborns. Each template includes a T2 and T1 structural template, a segmented labeled image classifying each tissue, and a set of probability maps for each tissue type. As expected, the structural templates of term newborns and preterms show great differences due to the maturation of the brain. The preterm template presents increased CSF volume, enlarged ventricles and decreased gyrification (Figure 1).

We used the labeled segmentation of the full-term and preterm templates to build a realistic forward model for the EEG source localization. Electrical brain activity generators can be regularly distributed into the cortical grey matter (Figure 2) and a given electrical conductivity can be assigned to each type of tissue.

Furthermore, these templates can also be used for analyses needing a mask. For instance, a mask of the tissues of interest can be easily built using the segmented template and used for subsequent analysis such as for constraining the ICA decomposition of resting state fMRI to the brain tissue, excluding ventricles.

Discussion and Conclusion: We built templates of preterm and full-term newborns' brain using segmentation of individual structural MRI. These templates with detailed tissue classification allow the building of realistic head models without having to resort to a CT-scan. Such head models are essentials for an accurate EEG source localization. Given that brain tissue properties are different at birth, these templates for preterms at term-equivalent age and term newborns are of great interest in the study of neurodevelopment and of the effect of prematurity. The tissue probability maps derived from these templates could be also used as prior to improve the automatic segmentation of the neonatal brain.

References: 1. Gui L., Lisowski R., Faundez T. et al. Morphology-driven automatic segmentation of MR images of the neonatal brain. Med Image Anal. 2012;16:1565-1579.

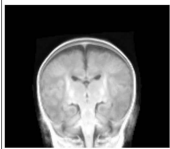
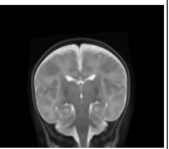
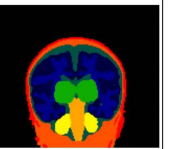
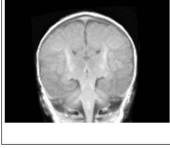
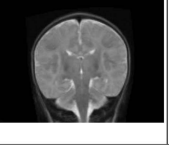
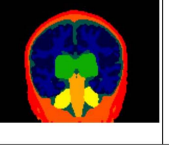
Template T1	Template T2	Segmentation	
			Preterm (N=21)
			Term (N=11)

Figure 1: Coronal view of the T1 and T2 templates and their corresponding segmentation labels for the preterm and full-term groups.

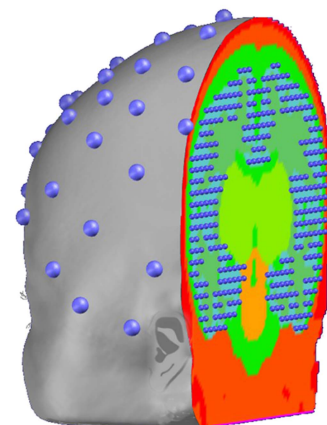


Figure 2: Realistic newborn head model. The solution points (small blue spheres) are regularly distributed into the grey matter. The positions of the EEG electrodes are represented at the surface of the head with blue spheres.