

Apparent Fibre Density Abnormalities in Adolescents Born Extremely Preterm: Moving Beyond the Diffusion Tensor

David Raffelt¹, Jeanie LY Cheong^{2,3}, Farnoosh Sadeghian¹, Deanne K Thompson^{3,4}, Peter J Anderson^{3,5}, Lex W Doyle^{2,3}, and Alan Connelly^{1,6}

¹Florey Institute of Neuroscience and Mental Health, Melbourne, VIC, Australia, ²Neonatal Services, Royal Women's Hospital, Melbourne, VIC, Australia, ³Victorian Infant Brain Studies, Murdoch Childrens Research Institute, Melbourne, VIC, Australia, ⁴Developmental Imaging, Murdoch Childrens Research Institute, Melbourne, VIC, Australia, ⁵Department of Paediatrics, University of Melbourne, Melbourne, VIC, Australia, ⁶Department of Medicine, University of Melbourne, Melbourne, VIC, Australia

Target Audience: Clinicians and neuroscientists with an interest in white matter neurodevelopment in preterm infants, and researchers that perform diffusion-weighted MRI and analysis.

Purpose: To investigate the effects of preterm birth and other neonatal clinical measures on white matter tracts in adolescents.

Introduction: Preterm birth is associated with increased risk of health and developmental problems in childhood and adolescence. White matter (WM) microstructure abnormalities have been reported previously in preterm born adolescence using diffusion tensor imaging metrics¹. Due to limitations of the tensor model in voxels containing crossing fibres, such differences are difficult to interpret. Apparent Fibre Density (AFD) provides a method based on the Fibre Orientation Distribution (FOD) that enables differences in individual fibre bundles to be identified², even in voxels containing multiple fibres. Positive correlation of AFD and gestational age (GA) has been reported in preterm born infants³. This study uses a geographical cohort of extremely preterm (EP) and term born adolescents to investigate whether EP birth leads to AFD abnormalities in specific white matter tracts that persist into adolescence. It also investigates whether there is correlation of AFD with a range of perinatal factors.

Methods: DWI data were obtained (45 directions, b-value 3000 s/mm², 3T Siemens Trio scanner) in 290 subjects including 149 EP (56 Male; GA < 28 weeks) and 141 term-born healthy aged matched controls (60 Male). Mean age of participants was 18 years old (range 16 to 20 years old). In the EP group, 37% had received postnatal corticosteroids (PNS), 7% had intraventricular haemorrhage grade 3 or 4 (IVH), 3% had cystic periventricular leukomalacia (PVL), and 24% had surgery.

Pre-processing involved motion and bias field correction, intensity normalisation, and up-sampling by a factor of 2⁴. FODs were computed by Robust Spherical Deconvolution⁵ using MRtrix⁶. A population-specific FOD template was generated from a subset of data (mix of 20 healthy controls and 20 EP subjects) and all FOD images were registered to that template⁷. AFD modulation was applied in the final transform⁴. Statistical analysis was performed with tractographic threshold-free cluster enhancement². Corrected p-values were assigned to each fixel (i.e. a specific fibre population within a voxel) using permutation testing (5000 permutations). Age, gender, and intra-cranial volume were considered as covariates of no interest for AFD comparison across subjects. For testing fixel-wise AFD correlations in the EP group with different variables (GA, BW, PNS, IVH, surgery and PVL) we included age and gender as covariates of no interest. To visualise statistically significant fixels, every point along each tractogram streamline was associated with a fixel (based on voxel location and streamline tangent) and displayed if the fixel had a significant p-value (p<0.05 corrected).

Results: We observed a reduction in AFD in the EP group compared to healthy controls within many WM tracts (p< 0.05, Fig 1a). For most affected WM structures, the effect size observed was ~10% (relative to controls); however the effect size was as large as 30% in some regions such as the splenium, posterior cingulum, and anterior commissure (Fig 1b). GA and BW correlated positively with AFD in the corpus callosum, inferior longitudinal fasciculus, cingulum and anterior commissure (Fig. 1c & d). As shown in Fig 1e, IVH correlated negatively with AFD in the splenium of corpus callosum. PNS were negatively correlated with AFD in most WM structures (Fig 1f). No significant correlations were observed between AFD and PVL or surgery.

Discussion and Conclusion: Previous work³ showed that AFD correlates with GA at birth. The present work indicates not only that AFD-GA correlations persist into adolescence, but also that a number of other factors such as EP birth itself and PNS treatment affect fibre tract development as evidenced by AFD in adolescence. Unlike previous whole-brain analysis of preterm diffusion MRI, we have identified abnormalities within specific white matter fibres, including in regions containing crossing fibres. Furthermore, abnormalities reported here are more extensive than previous tensor-based methods¹⁰, suggesting AFD is both a sensitive and specific measure of white matter pathology.

References: [1] Eikenes L et al., Neuroimage 54, 1774-1785 (2011), [2] Raffelt D et al., Proc. ISMRM 21, 841 (2013), [3] Tournier D et al. 21, 0797 (2013), [4] Raffelt D et al., Neuroimage 59, 3976-3994 (2012), [5] Tournier D et al., Proc. ISMRM 21, 0773 (2013), [6] Tournier D et al., Int. J. Imag. Sys. Technol. 22, 53-66 (2012), [7] Raffelt D et al. (2011) NeuroImage 56(3):1171-80, [8] Tournier D et al., Proc. ISMRM 18, 1670 (20), [9] Smith RE et al., Neuroimage 67, 298-312 (2013), [10] Allin A et al. PLoS ONE 6:10 (2013)

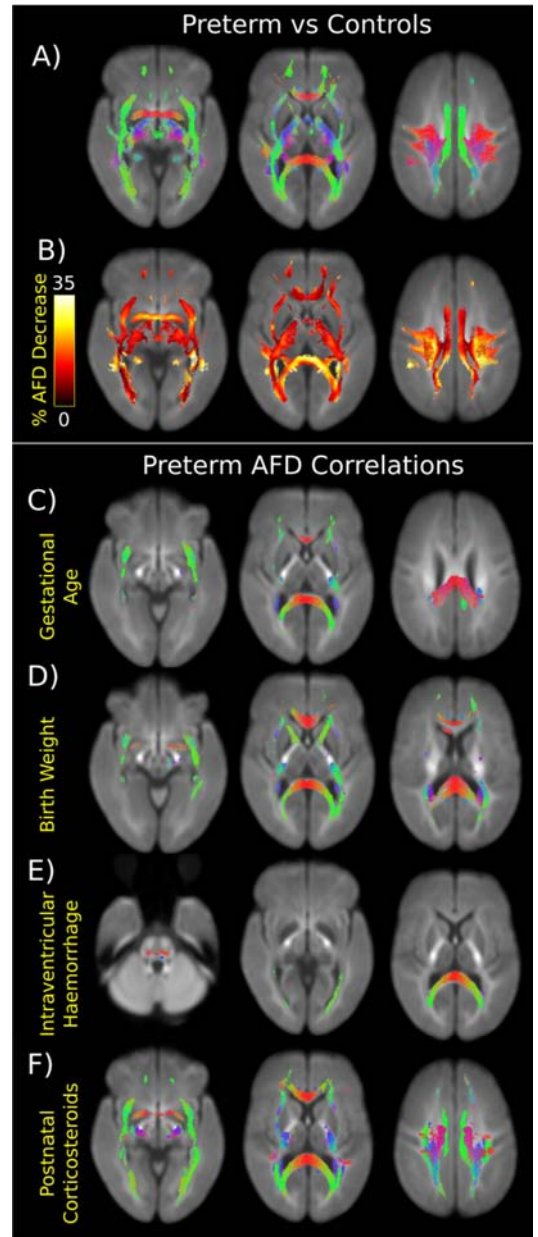


Figure 1. Apparent fibre density (AFD) results shown in series of axial slices for different analysis. Streamlines displayed correspond to significant fixels (fibre populations within a voxel) (p<0.05 corrected). (a) Significant AFD decreases in EP compared to healthy controls (coloured by direction Red:L-R, blue:I-S, green: A-P) (b) Effect size displayed as percentage AFD decrease relative to control group. Significant correlations observed between AFD and (c) GA, (d) BW, (e) IVH, (f) PNS in the EP group.