

## EXPLORING THE MECHANISM OF EMOTIONAL IMAGERY IN ADOLESCENCE WITH FMRI

Marta Re<sup>1</sup>, Barbara Tomasino<sup>2</sup>, Carolina Bonivento<sup>1</sup>, Filippo Arrigoni<sup>3</sup>, Matteo Balestrieri<sup>1</sup>, and Paolo Brambilla<sup>1</sup><sup>1</sup>RUBIN, ICBN, University of Udine and University of Verona, Udine, Italy, <sup>2</sup>Scientific Institute, IRCCS Eugenio Medea, San Vito al Tagliamento, Pordenone, Italy, <sup>3</sup>Neuroimaging, Scientific Institute, IRCCS Eugenio Medea, Bosisio Parini, Lecco, Italy

## INTRODUCTION

Mental imagery strongly influences the experience of emotion and a number of psychological disorders manifest distressing abnormalities in mental imagery. During childhood and adolescence, neurocognitive development impacting mental imagery processes may moderate its relationship with clinically-relevant emotional symptoms and these changes could impact vulnerability to distressing mental imagery. Using fMRI (functional Magnetic Resonance Imaging) it is possible to study how the mental imagery works in adolescence by exploring the interaction between different kind of imagery like the emotional and motor imagery. It thus has been demonstrated that motor imagery and executed movement share cortical networks [1] and that processing of action-related words involves activation of the motor circuitry. Furthermore, in the presence of motor phrases there is an enhanced M1 activation for imagery compared to letter detection of motor vs. non-motor phrases [2-4]. The letter detection task can be used as an inhibitors of the imagery and then it can be act as a control. The aim of the study was: 1) to explore the networks underlying emotional imagery and 2) to do this during brain development, ie adolescence.

## METHODS

15 subjects (10 males) aged between 14 and 19 years (mean age  $16.41 \pm 1.32$  years) were excluded from having a psychiatric diagnosis. They underwent a MR scanning session including a T2\*-weighted EPI sequence (TR/TE: 2500/30, In-plane resolution: 1.8 x 1.8 mm, Thickness: 3 mm, Nr of slices: 30, Field of view: 64 x 64 mm, Nr of volumes: 612) using a 3T Achieva MR scanner (Philips, The Netherlands) with a 8 channel head coil. The fMRI protocol consisted in a event related visual stimulation in which the subjects were asked to perform Mental Imagery "I" and Letter Detection "LD" and were presented with Motor "M" and Emotional "E" related verbs. In order to make sure that subjects were concentrating on the meaning of the verbs, they were asked to give a pleasantness judgment ("Silently read the phrase and imagine the situation. Do you like it?") and to perform a letter detection task ("Silently read the phrase and report whether the letter "S" is present"). The subjects had to press a button in response to the questions. In total were presented 144 trials, 36 for each stimulus "I\_M", "I\_E", "LD\_M", "LD\_E", (in total 72 trials "E", 72 "M", 72 "L\_D" and 72 "I"). The data processing was performed with SPM5 [7] (<http://www.fil.ion.ucl.ac.uk/spm/>). FMRI preprocessing included: 3D head-motion correction, spatial smoothing of 6 mm FWHM, temporal high pass filter and linear trend removal. Anatomic 3D data set was segmented, normalized and coregistered with the functional information. An event related analysis and a subsequent t-test second level statistical analysis were performed also by using age and sex as covariates. The attention was focused on two interactions: Int1 "(LD\_E - LD\_M) - (I\_E - I\_M)" and Int2 "(I\_E - I\_M) - (LD\_E - LD\_M)". The resulting activations were thresholded ( $p < 0.001$  and cluster correction of 50 voxels). The anatomical localization of the activations was done by using the SPM Anatomy Toolbox v1.8 [8]. For interpreting the interaction the beta values, extracted for each individual subject for all of the clusters, were analyzed by means of an ANOVA.

## RESULTS

Int1 did not show a significant activation. On the contrary, Int2 showed activation within several clusters (see Figure 1). Cluster 1 involves the right insula (extending to the superior temporal gyrus and the rolandic operculum). Cluster 2 is located in the left areas 3, 4 and 6 (primary motor cortex, premotor cortex and primary somatosensory cortex), while cluster 3 includes the right premotor cortex and the right superior and middle frontal gyrus. Cluster 4 involved the somatosensory cortex. Cluster 5 concerned the left superior temporal gyrus. Cluster 6 implicated the left inferior parietal cortex (extending to the supramarginal gyrus and the postcentral gyrus). Cluster 7 is localized in the right superior and inferior parietal cortex (extending to the primary somatosensory cortex). Finally, cluster 8 involved the left superior parietal lobule (extending to the left postcentral gyrus and the somatosensory cortex). The ANOVA showed that while activation in clusters 1, 4, 6 and 8 was driven by motor imagery, activation in clusters 3, 5 and 7 (the right premotor Cortex, the right superior and middle frontal gyrus, the left superior temporal gyrus, the right superior and inferior parietal cortex and the primary somatosensory cortex) was driven by the emotion imagery. Conversely, cluster 2 appears to be principally involved in the Motor Letter Detection.

## DISCUSSION

The joint analysis of the areas involved in the active clusters (Figure 1) for the "(I\_E - I\_M) - (LD\_E - LD\_M)" interaction, representing the areas differentially activated by emotional imagery (but not by motor imagery) as controlled by letter detection, and the ANOVA on the mean beta values extracted by the respective clusters showed an activation in i) the right premotor cortex (extending to the right superior and middle frontal gyrus), ii) the left superior temporal gyrus, and iii) the right superior and inferior parietal cortex (extending to the primary somatosensory cortex). Some evidence of the involvement of these areas in emotional imagery can be found in a recent study [7] that have found that mental imagery of an object or event can cause the activation of sensory cortical components. Also another study demonstrated that autobiographical memory can cause activity in sensory cortex [8]. Some investigations among flashbacks in PTSD (Post-Traumatic Stress Disorder) found increased activity in sensory and motor cortical regions and in supplementary motor areas [9]. Moreover, it is known that the parietal cortex is involved in theory of mind states and thus can be related to imagery. It has been demonstrated that the superior temporal gyrus is involved in the emotional processing, while the superior and middle frontal gyrus are areas that are recruited during cognitive control and mnemonic encoding of general stimuli [10-12]. Only one study [13], that investigated the neural correlates of flashbacks in healthy adults, showed an increase in activity of the bilateral middle temporal gyrus and of the left inferior frontal gyrus. In summary, these results are only preliminary but examining emotional imagery seems to be a promising approach to further analysis of the mechanism of imagery in the adolescence. However, more investigations along these lines are necessary to better understand the neural bases of normal development of the brain.

## REFERENCE

[1] N. Sharma and J.C. Baron, 2013. [2] B. Tomasino et al., 2007. [3] B. Tomasino et al., 2010. [4] C. E. Watson, 2013. [5] Karl J. Friston et al., 2007. [6] S.B. Eickhoff et al., 2005. [7] Moulton and Kosslyn, 2009. [8] Cabeza and St Jacques, 2007. [9] Whalley et al., 2013. [10] Elliott et al., 2000. [11] Compton et al., 2003. [12] Banich et al., 2009. [13] Bourne et al., 2012.

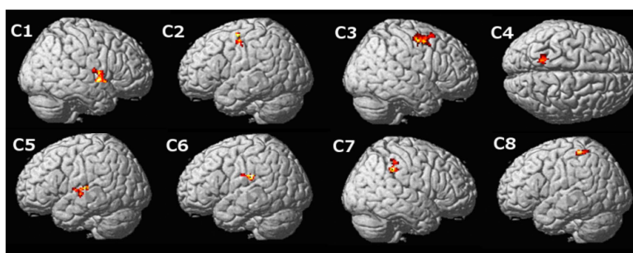


Figure 1: Activation of the 8 clusters (C1, C2, C3, C4, C5, C6, C7, C8) for Int2.