

Multiparametric Analysis using pCASL, IVIM and DKI for Head and Neck Squamous Cell Carcinoma

Noriyuki Fujima¹, Daisuke Yoshida¹, Tomohiro Sakashita¹, Akihiro Homma¹, Yuriko Suzuki², and Kohsuke Kudo¹

¹Hokkaido University Hospital, Sapporo, Hokkaido, Japan, ²Philips Electronics Japan, Tokyo, Japan

Purpose

Tumor diffusion and perfusion is important factor for the assessment of head and neck squamous cell carcinoma (HNSCC) [1]. In recent years, advanced and noninvasive technique for the measurement of tissue diffusion and perfusion has been developed. Pseudo-continuous arterial spin labeling (pCASL) has been widely used for the quantitative assessment of tissue perfusion [2]. Intravoxel incoherent motion (IVIM) has been also used for the measurement of both tissue perfusion and diffusion using by bi-exponential fitting to multi b-value diffusion weighted imaging (DWI) [3]. In addition, diffusion kurtosis imaging (DKI) has introduced as a new concept in DWI that quantifies the deviation of tissue diffusion from a Gaussian pattern [4]. The aim of this study was to evaluate diagnostic value of the pCASL, IVIM and DKI as multi-parametric analysis in HNSCC by assessing its usefulness as predictor of local control of primary tumor.

Methods

Twenty four consecutive patients with HNSCC underwent pCASL, IVIM and DKI by using a 3.0-Tesla unit (Achieva TX; Philips Medical Systems, Bests, the Netherlands) with a 16-channel neurovascular coil. Parameters of pCASL were as follows; TR 3554 ms, TE 14 ms, labeling duration 1650 ms, post labeled delay 1280 ms, FOV 24 × 24 cm, matrix 80 × 80, slice thickness 5 mm × 15slices, readout; multishot spin-echo echo-planar imaging, scan time 5'05. For obtaining the data of IVIM and DKI, multi b-value DWI was acquired using single-shot spin-echo echo-planar imaging. Three orthogonal motion probing gradient was used with b-value of 0, 10, 20, 30, 50, 80, 100, 200, 400, 800, 1000, 2000. Other parameters of the DWI were as follows; TR, 5000 ms; TE, 64 ms; FA, 90 degree; FOV, 230_230 mm; 64_64 matrix; slice thickness, 5 mm×25 slices; SENSE factor 2.0; scanning time, 4' 37. All b-point data was used for IVIM analysis, and b-point of 0, 800, 1000, and 2000 was used for DKI analysis. Tumor blood flow (TBF) was quantitatively calculated using pCASL data. For IVIM analysis, true diffusion coefficient (D), pseudo diffusion coefficient (D*), and perfusion fraction (f) were calculated respectively. In addition, kurtosis value (K) was calculated from DKI data. All patients were treated by super-selective arterial infusion of cisplatin with concomitant radiotherapy (total 65 Gy). MR scanning was performed before treatment and at early treatment period (time point of 15~22 Gy in 65 Gy). After the treatment, multi-modality assessment by using FDG-PET, CT, MRI and follow-up (4-27 months, median 15 months) were performed to determine treatment responders (CR) or non-responders (non-CR). Multivariate statistical analysis was performed to determine the diagnostic accuracy in dividing CR and non-CR group by using pCASL (TBF), IVIM (f, D, D*) and DKI (K). Pre-treatment and early treatment period of TBF, f, D, D*, K and change ratio in each parameter between the two time periods were used for this analysis.

Results

After the treatment, nineteen patients were determined as CRs and five patients non-CRs. Significant relationship was observed in pre-treatment TBF, pre-treatment f, change ratio of D, K between pre-treatment and early treatment period for the division of CR and non-CR group (Figure 1-4). Diagnostic accuracy of pretreatment TBF was 0.83, f was 0.83, change ratio of D, K between pre-treatment and early treatment period was 0.86 and 0.79 respectively. Diagnostic accuracy by combining these 4 parameters was 0.92.

Discussion

Although TBF by pCASL, f and D by IVIM and K by DKI were respectively useful for the assessment of HNSCC to determine whether successful local control of primary tumor was obtained or not, highest diagnostic accuracy can be obtained by combining these parameters. Moreover, these technique of pCASL, IVIM, and DKI, being completely noninvasive, can be easily performed for evaluation of the tumor diffusion and perfusion repetitively any time in the treatment period without concern on patient's renal dysfunctions commonly among patients with treatment of cisplatin, a condition in which contrast media should be avoided.

Conclusion

Noninvasive multiparametric evaluation of tumor diffusion and perfusion by combining pCASL, IVIM, and DKI can provide high diagnostic accuracy for the assessment of HNSCC to determine whether successful local control of primary tumor was obtained or not.

References

[1] AJNR Am J Neuroradiol.2012;33(4). [2] Magn Reson Med. 2007;58(5):1020-7. [3] Radiology. 1988;168(2):497-505. [4] Magn Reson Med. 2005;53(6):1432-40.

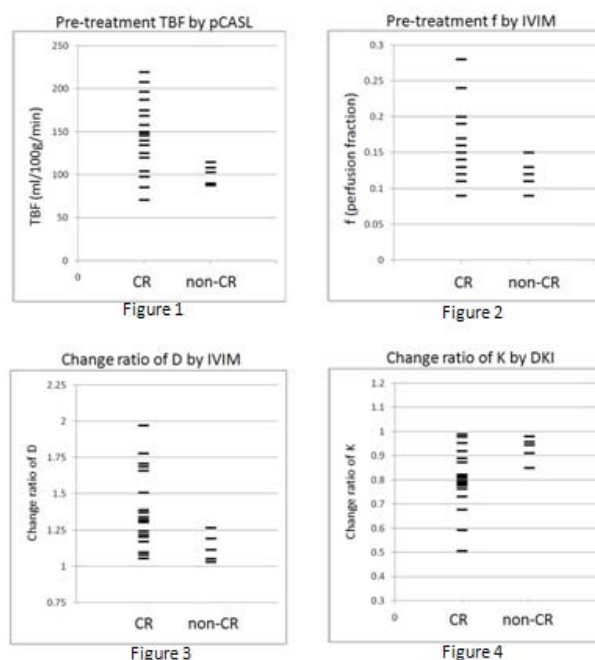


Figure1~4; Distribution of each parameter which was observed relationship between CR or non-CR group by multivariate statistical analysis.