

## Tractography of the trigeminal nerve using 7T MRI

Christophe Lenglet<sup>1</sup>, Julien Sein<sup>1</sup>, Julian Tokarev<sup>2</sup>, Andrew W Grande<sup>3</sup>, Bharathi Jagadeesan<sup>4</sup>, and Pierre-Francois Van de Moortele<sup>1</sup>

<sup>1</sup>Center for Magnetic Resonance Research, University of Minnesota, Minneapolis, MN, United States, <sup>2</sup>University of Minnesota, Minneapolis, MN, United States,

<sup>3</sup>Department of Neurosurgery, University of Minnesota, Minneapolis, MN, United States, <sup>4</sup>Department of Radiology, University of Minnesota, Minneapolis, MN, United States

**Target audience:** Clinicians and researchers interested in trigeminal neuralgia.

**Purpose:** To leverage 7T diffusion MRI to reconstruct the three-dimensional course of fiber pathways from the individual divisions of the trigeminal nerve at the skull base.

**Introduction:** Trigeminal neuralgia (TN) is a neurological disorder, which is characterized by intermittent episodes of acute lancinating facial pain produced by exposure to non-painful and often routine stimuli such as light touch or brushing one's teeth. It is one of the most painful disorders encountered in humans and can have a significant adverse effect on the psychological and physical well being of affected patients [1,2]. Although a variety of treatment options such as microvascular decompression or radiofrequency thermorhizotomy have emerged for this disorder, the current incomplete understanding of its etiopathogenesis means that these treatments are almost universally based on empirical evidence. The most widely held view is that TN is a result of an abnormal degree of compression of the trigeminal nerve by adjacent vascular loops at the skull base, or so called *neurovascular conflict*. The evidence for this hypothesis is predominantly based on the success of surgical microvascular decompression (MVD) procedures in obtaining pain relief in patients with this disorder [3,4]. However, the high recurrence rate of symptoms in these patients, after MVD and other procedures, suggests that newer treatment strategies based on an improved understanding of this disorder are needed. Detailed microstructural imaging studies of the trigeminal nerve [5] using high field MRI techniques could potentially improve our understanding of this disorder and help develop better treatment techniques.

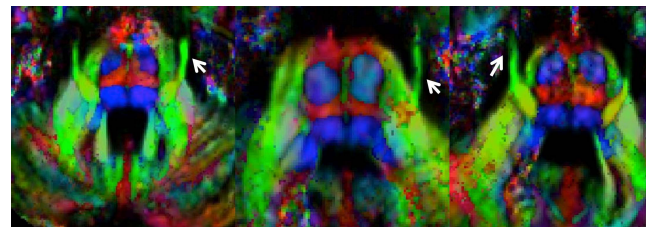
**Methods:** All images were acquired using a 7 Tesla MRI system (Siemens, Erlangen, Germany) equipped with a volume transmit, and a 24-channel receive head coil (Nova Medical, Inc. Wilmington, MA, USA). Images were collected on six healthy volunteers. The protocol includes: *T1w MPRAGE*, voxel size=0.6x0.6x0.6mm<sup>3</sup>, TR/TE/TI=3000/3.5/1500ms; *diffusion MRI*, voxel size=1.2x1.2x1.2mm<sup>3</sup> (reconstructed at 0.6x0.6x1.2mm<sup>3</sup> with zero filling), 18 slices, TR/TE=5000/63.7ms, 100 gradient directions, *b*-value=1000 s/mm<sup>2</sup>, 11 additional *b*=0 volumes.

**Results and discussion:** Following distortions and head motion correction [6], fiber orientation mapping (Fig. 1) was performed and a seed region at the nerve root exit level was placed to perform probabilistic tractography [7] of the nerve. From this first reconstruction result, the anterior projections of the trigeminal nerve were subsequently visually identified and delineated as individual seed areas to isolate the ophthalmic (V1), maxillary (V2) and mandibular (V3) branches, thereby producing representations of their individual three-dimensional course, and relative positions within the nerve root and trigeminal ganglion (Fig. 2).

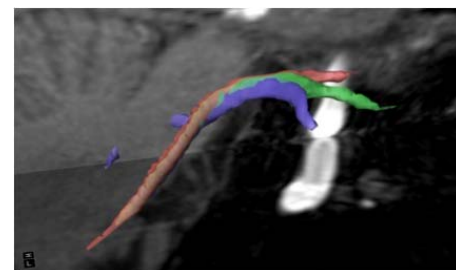
**Conclusion:** This work demonstrates that it is possible to generate detailed reconstructions of the trigeminal nerve divisions using 7T diffusion MRI and tractography. This also opens up new avenues for studying the pathophysiology of TN, which could eventually result in better treatment techniques for this disorder.

**References:** [1] Benoliel et al., *Oral Maxillofac Surg Clin North Am*, 2008; [2] Carlson, *Oral Maxillofac Surg Clin North Am*, 2008; [3] Dandy, *Am. J. Surg.*, 1934; [4] Jannetta, *J. Neurosurg.*, 1967; [5] Hodaie et al. *PLoS ONE*, 2012; [6] Andersson et al., *ISMRM 2012*; [7] Behrens et al., *Neuroimage*, 2003.

**Acknowledgements:** Partly supported by NIH grants P41 EB015894, P30 NS5076408, S10 RR026783.



**Fig. 1.** Principal axonal pathway orientation estimated from diffusion MRI in 3 subjects. White arrows indicate the trigeminal nerve. Color code is red: left-right; green: anterior-posterior; blue: inferior-superior.



**Fig. 2.** Tractography of the trigeminal nerve and identification of the ophthalmic (red), maxillary (green) and mandibular (blue) branches.