

THREE-DIMENSIONAL MORPHOLOGICAL FEATURES FOR DETECTION OF DEGENERATION IN THE PCL FROM MAGNETIC RESONANCE IMAGES AT 3T: A FEASIBILITY STUDY

Katharine J Wilson¹, Jurgen Fripp², Kaikai Shen², Rachel K Surowiec¹, and Charles P Ho¹

¹Steadman Philippon Research Institute, Vail, CO, United States, ²CSIRO Computational Informatics, The Australian eHealth Research Centre, Queensland, Australia

PURPOSE: Diagnosis of the structural integrity and health of the posterior cruciate ligament (PCL) via conventional MRI has proved variable [1]. Following a chronic injury, the PCL is often affected by degeneration with symptoms including thickening and elongation of the ligament. The ability to accurately quantify changes in shape would be valuable in the clinical diagnosis of PCL injuries. Statistical shape models (SSMs) may provide a useful clinical tool for characterizing the normal shape variations in a population, and determining when a patient deviates from this. The purpose of this study was to create an SSM for the PCL in an asymptomatic population using MRI ligament models and quantify the variation in PCL shape. To our knowledge there are no published studies which have analysed the morphology of the PCL quantitatively using SSMs.

METHODS: Twenty seven asymptomatic subjects were recruited for this study (aged 26-60 years, 13 males and 14 females, 14 right and 13 left). Subjects had no prior knee surgery and were deemed asymptomatic through an objective clinical examination, subjective score, and morphologic MR evaluation. Unilateral knee images were acquired on a 3T MRI system (Magnetom Verio, Siemens Healthcare, Erlangen, Germany). The study was internal review board approved and all subjects were prospectively enrolled with informed consent. The asymptomatic knee for each participant was imaged using a 15-channel multi-element phased-array knee coil (Quality Electrodynamics, LLC, OH, USA) and a standard clinical protocol with T2 mapping sequences was used (TR/TE: 2000/10.7-74.9 ms; VS: 0.6x0.6x2mm; FOV: 80mm; AT: 4:44; sagittal plane).

Group	Age				Gender	
	Mean	STD	Min	Max	Male	Female
Young	27.7	1.8	25	31	6	3
Mid	35	1.8	33	39	4	5
Older	56.9	3.1	50	60	1	8
Total	39.9	12.6	25	60	11	16

Three-dimensional PCL volumes were derived from the MR images using semi-automated segmentation software (Mimics, Materialise, Plymouth, MI, USA). This was performed by three orthopaedic physicians at two time points separated by a month. The segmentations were exported as a binary image series, and custom software was used to convert these into an Analyze image volume [2]. As the T2 maps contain highly anisotropic voxelization (0.625x0.625 with 2mm thickness and 0.4 mm slice gap) an in-house implementation of a shape based interpolation scheme [3] was used to up-sample the binary masks to (0.625x0.625 x 0.8 mm) and a marching cube surface was extracted and smoothed using a windowed sinc function with passband of 0.1 [4].

The SSM and correspondence labelling for each PCL surface was generated using the approach outlined in Shen et al. [5]. In this approach nP landmarks on the surface of PCL are reparameterized using an optimization scheme to avoid the false variation induced by incorrect correspondences. This correspondence problem can be solved by optimization of an information theoretic objective function based on the minimum description length (MDL) of the shape model [6]. In this study, the PCL surfaces in the training set were first registered and aligned via similarity body transformations (ICP). The correspondence of landmarks over the training set is established by a groupwise optimization and fluid regularization on the shape image [6]. For each target surface not in the training set, the correspondence is propagated to the target surface by optimizing a L1 distance metric between the SSM and the surface.

RESULTS:

There was a significant difference in absolute volumes between age and gender groups (with $p < 0.05$). The primary Eigen-modes for the SSM can be seen in Fig 1a, with most changes observed in terms of the length and size of the anterolateral and posteromedial bundles. A moderate correlation between age and shape changes per vertex was observed (Fig 1b). There was no significant inter-rater and intra-rater shape difference found using Hotelling's T2 (with $p=0.05$ FDR corrected). Similarly, no significant difference was found in shape between males and females, however a trend was observed with the length and thickness of the PCL larger in males than females (Fig 2). No significant difference in shape was found between age groups; although larger mean group differences were observed between the young (< 30 years old) and the two other groups (Fig 3), with only minimal differences observed between middle (30-40 year olds) and older (50+ years old) groups (Fig 4).

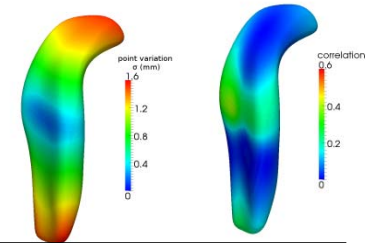


Fig 1: Average PCL with (a: left) First eigen-mode (sigma in mm). (b: right) Correlation with age.

DISCUSSION AND CONCLUSION: We present the anatomical variability seen in a cohort of 27 asymptomatic PCL with mixed age and gender analysed using SSM. After pre-processing and size normalization, there was no significant effect of age and gender found on the SSM, however some trends were observed. Larger numbers of PCLs segmented on higher resolution MR images will be acquired to confirm these findings. In addition, any relationship with joint or bone size will also be explored. This model will provide a baseline for comparison of the shape changes following a PCL injury.

REFERENCES:

- [1] Servant, Knee. 2004;11(4):265-70,
- [2] <http://research.ict.csiro.au/software/milxview>
- [2] Herman, CGA, 1992, 12(3):69-79,
- [3] Taubin, ECCV, 1996 1064:283-292,
- [4] Shen, Neuroimage. 2012;59(3):2155-66,
- [5] Davies, MIA, 2008;12(6)787-796

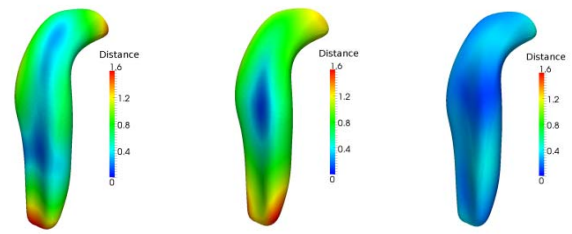


Fig 2: PCL with colour map showing | male - female | in mm. Fig 3: Average PCL with colour map showing | young - old | in mm. Fig 4: Average PCL with colour map showing | mid - old | in mm.