

AUTOMATED ANALYSIS OF THREE-DIMENSIONAL MANDIBULAR MOVEMENT USING MULTI-SECTION DYNAMIC MRI

Ryusuke Nakai¹, Takashi Azuma², Keiji Shigeno¹, Mariko Wakatsuki¹, Guoxiang Liu², Osamu Takizawa³, and Hiroo Iwata¹

¹Institute for Frontier Medical Sciences, Kyoto University, Kyoto, Japan, ²Center for Information and Neural Networks, National Institute of Information and Communications Technology, Osaka, Japan, ³Siemens Japan K.K., Tokyo, Japan

Introduction: The number of patients with temporomandibular joint disease has increased in recent years. This presents a challenge in dental and oral surgery because the causes of temporomandibular joint disease have not been identified and treatment has not been established. This is due to the association of complicated factors such as joint abnormality and muscle tone with the complex structure and movement of temporomandibular joints. These joints (articular disks) are positioned between the mandible and maxilla on the right and left side. Thus, mandibular movement is associated with three-dimensional movement of the articular disks and several muscles, and is extremely complex. The disks also tend to deviate from their positions and dislocation of the articular disks causes many disorders. The situation is further complicated because these abnormal movements differ from person to person. To address these issues, isolation and discrimination of individual problems and establishment of evaluation and treatment methods for each problem are important. Analysis and visualization of mandibular movement with X-ray images and CT are currently performed, but these methods have the major problem of X-ray exposure. MR imaging allows biological information to be obtained without X-ray exposure, and safe evaluation and analysis of mandibular movement has become possible using MRI. However, movement analyses of time-series images obtained in a single two-dimensional plane cannot identify or measure all movement, and previous studies have not had sufficient accuracy and objectivity for measurement using manual operation. In the current study, a technique was developed for continuous time-series mandibular imaging of multiple sections with analysis of time-series data and automatic measurement of the three-dimensional positions and rotation angles of the mandibular movement. The utility of this technique was evaluated by analysis of mandibular movement in volunteers.

Methods: The subjects were 7 adult volunteers who gave informed consent after receiving an explanation of the study. All MRI experiments were performed using a 1.5T whole body scanner (Magnetom Sonata, Siemens AG, Erlangen, Germany) and a CP head array coil. Mandibular movement was evaluated by multi-section dynamic imaging performed with the True FISP sequence (TR: 5.43ms, TE: 2.72ms, pixel size: 0.684x0.684mm, flip angle: 70deg., thickness: 3mm)^{1,2}. The planned imaging sections were the right- and left-sided mandibular condylar surfaces for obtaining trajectories of the articular disks and mandibular condyles; the median sagittal section for the trajectory of the mandibular central incisor, which is the most general measurement point when evaluating mandibular movement; and the transverse section for transverse movements of the temporomandibular joints, including the right and left mandibular condyles, during mouth opening and shutting. Scanned images were processed for measuring the mandibular condyle position using manual and automatic operations. The automatic extraction process is based on matching of basic shape using signal data for the mandibular condyle and an evaluation function, through which the position and rotation angle of the mandibular bone are recognized. The results of manual and automatic measurements were compared. Automatic measurement data for typical subjects were input into a three-dimensional skull model made from CT data.

Results and Discussion: Loci of the top position of the mandibular condyle measured manually and automatically are shown in Fig. 1. The two trajectories were found to match satisfactorily. The mean positional differences of each trace point between the automatic and manual processes calculated in each direction were 0.27 mm (x), 0.32 mm (y) and 0.30 mm (z). The rotation angles of the mandibular condyle measured manually and automatically are shown in Fig. 2. The automatic measurement technique had very good precision. Images of a skull model with input of mandibular movement data of typical subjects obtained using the automatic technique are shown in Fig. 3. These images permit direct viewing of the mandibular movement. Therefore, this technique should permit rapid diagnosis of symptoms and disorders by dentists.

Conclusion: Temporomandibular joint disorder and mandibular movement disturbance are diseases in which evaluation and diagnosis are difficult. Images obtained using MRI provide information on mandibular movement and internal tissue that is not available using other techniques. In this study, we developed a new approach for automatic measurement of mandibular trajectories and parameters from MR images. This technique gives precise information that can facilitate diagnosis of temporomandibular joint disorder and mandibular movement disturbance. Our planned development of a support system for temporomandibular joint disorder evaluation and treatment will further increase the diagnostic utility of these MR images.

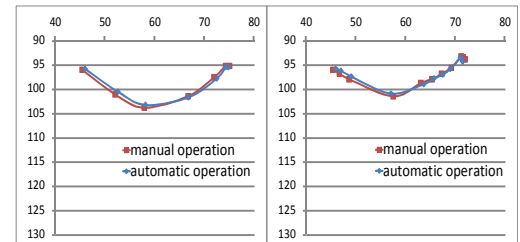


Fig. 1. Loci of the top position of the mandibular condyle measured manually and automatically. (Left) opening. (Right) closing.

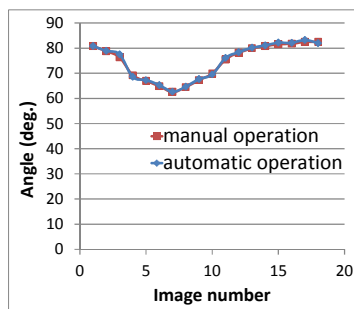


Fig. 2. The rotation angles of the mandibular condyle measured manually and automatically.

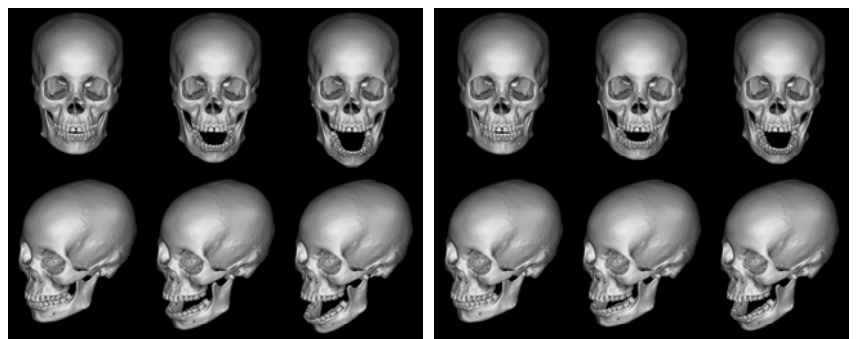


Fig. 3. 3D visualization of the mandible movement measured automatically. (Left) a normal subject. (Right) a mandibular movement disturbance subject.

References: [1] Azuma T et al., Magn. Reson. Imaging, 2009; 27(3): 423-33. [2] Nakai R et al., Proc. ISMRM, 2012; 21: 3520.