

# Improved delineation of blood vessels in fingers with high-resolution non-contrast-enhanced time-of-flight MR angiography

Wingchi Edmund Kwok<sup>1,2</sup>, Zhigang You<sup>1</sup>, and Christopher Ritchlin<sup>3</sup>

<sup>1</sup>Department of Imaging Sciences, University of Rochester, Rochester, New York, United States, <sup>2</sup>Rochester Center for Brain Imaging, University of Rochester, Rochester, New York, United States, <sup>3</sup>Department of Medicine, University of Rochester, Rochester, New York, United States

## TARGET AUDIENCE

MR angiography and musculoskeletal MRI researchers, radiologists, researchers in systemic sclerosis and arthritis, rheumatologists

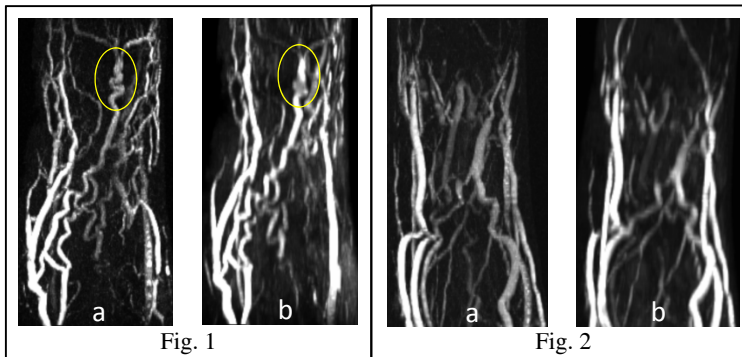
## PURPOSE

Blood vessel changes in fingers may occur in the early stage of systemic sclerosis (SS)<sup>1,2</sup> and arthritis<sup>3,4</sup>. Due to the small size of the blood vessels involved, finger angiography is challenging and demands very high image resolution. The development of specialized RF coils that provide high signal sensitivity<sup>1,5</sup> enables the resolution in MR angiography (MRA) of fingers to be significantly increased. In this study, we obtained finger MRA using a resolution that is significantly higher than those used in related studies by other groups, and compared our results with the data acquired using the highest resolution we found in those studies.

## METHODS

The study was conducted on a Siemens TRIO 3T system using a dedicated RF phased array receiver coil developed for finger MRA<sup>5</sup>. A regular 2D TOF sequence was modified for smaller FOV and thinner slice acquisition via pulse sequence programming by increasing the RF excitation pulse width from 2ms to 5ms, decreasing the bandwidth-time-product from 2.7 to 2.0, and modifying the pre-set limits on FOV and slice thickness. The index fingers of two normal male subjects (age 69 and 33) were imaged in the axial plane with TR 21ms, TE 9ms, FOV 31x31mm<sup>2</sup>, matrix size 256x256, slice thickness 0.4mm, 120 slices with zero-overlapping and scan time 10:58mins. For comparison, another scan was acquired using similar resolution as in a published study<sup>1</sup>, with TR 19ms, TE 7.3ms, FOV 40x28mm<sup>2</sup>, matrix 256x180, slice thickness 1.2mm, 80 slices with 50% overlapping and scan time 3:37mins. Maximum intensity pixel (MIP) display of the data was used in the evaluation.

## RESULTS



Figs. 1 and 2 show MIP displays of the higher (a) and lower (b) resolution data for the two subjects. The higher-resolution images give sharper and more definitive depiction of the blood vessels, enabling better visualization of the geometry and connectivity of the blood vessels as well as the relationship between the vessels. A twisted section of a blood vessel on the dorsal side of the finger just superior to the distal inter-phalangeal joint (circles in Fig. 1) was clearly delineated on the higher resolution but not on the lower resolution images.

## DISCUSSION

Our high-resolution technique shows significant improvement in the depiction of detailed vascular structures in fingers compared to data obtained with a resolution that is 5.0 times lower (in terms of acquired voxel volume). The differences in performance will be even greater when compared with typical finger MRA studies. Our technique should be valuable to SS and arthritis studies. For example, as SS patients suffer from loss of blood vessels in fingers<sup>1</sup>, the ability to reveal detailed conditions of the vessels should facilitate early assessment. Our technique may also be useful for distinguishing between arthritis with different blood vessel patterns<sup>6</sup>. A trade-off for using the higher resolution is that the signal will be lower, and some vessels may appear not as bright. In addition, since higher-resolution acquisition requires a larger number of slices to provide the same longitudinal coverage, the scan time will be longer but it can be shortened by several folds with the use of compressed sensing<sup>7</sup>. Our technique should be extendable to contrast-enhanced studies, though non-contrast-enhanced studies offer the advantages of avoiding nephrogenic systemic fibrosis induced by gadolinium and allowing repeated scanning.

## CONCLUSION

The high-resolution finger MRA technique reveals detailed blood vessel information not observable with resolution commonly used in research and clinical finger MRA studies. It should be useful for the diagnostic and treatment evaluation as well as pathogenesis studies of SS and arthritis.

## REFERENCES

1. Wang J, et al. *Rheumatology* 2008;47:1239-1243.
2. Lim RP, et al. *Radiology* 2009;252:874-881.
3. Vasanth LC, et al. *J Rheumatol.* 2010;37:1129-1135.
4. Fukae J, et al. *Arthritis Care Res* 2010;62:657-663.
5. Kwok et al. *ISMRM* 2013, p 4477.
6. Ritchlin CT, et al. *J Clin Invest.* 2003;111: 821-831.
7. Kwok et al. *ISMRM* 2013, p 2618.