

High resolution $T_{1\rho}$ -mapping in human wrist cartilage with a SAR and SENSE optimized coil at 7T

Mark W. J. M. Gosselink¹, Joep van Oorschot¹, Alexandra de Rotte¹, Fredy Visser¹, Peter R Luijten¹, Mies A Korteweg², Hanneke J. J. Bluemink¹, and Dennis W. J. Klomp¹

¹Radiology, UMC Utrecht, Utrecht, Utrecht, Netherlands, ²Radiology, AMC Amsterdam, Amsterdam, Noord-Holland, Netherlands

Introduction

$T_{1\rho}$ -mapping is a promising technique for the assessment of articular cartilage degradation, so far mainly applied in the knee¹. To assess the thin cartilage layers in the wrist high spatial resolution is required. Increased SNR at 7 T may fulfil this requirement. However, $T_{1\rho}$ -mapping uses long duration spin-lock pulses with high and uniform B. Both these conditions are not easily met at higher field strengths due to the concomitant SAR constraints and the intrinsic inhomogeneous B1 field at high Larmor frequencies. In addition, the higher resolution comes with more spatial encoding which requires high SENSE factors. In this study, we have developed a shielded wrist coil that confines its SAR hotspots to the extremities facilitating high SAR values. Moreover, as the RF wavelength is longer than the dimensions of the wrist, B1 can remain uniform and strong. Combined with a high density 32 channel receiver array we demonstrate high resolution $T_{1\rho}$ mapping of cartilage in the wrist at an isotropic resolution of 0.5 mm.

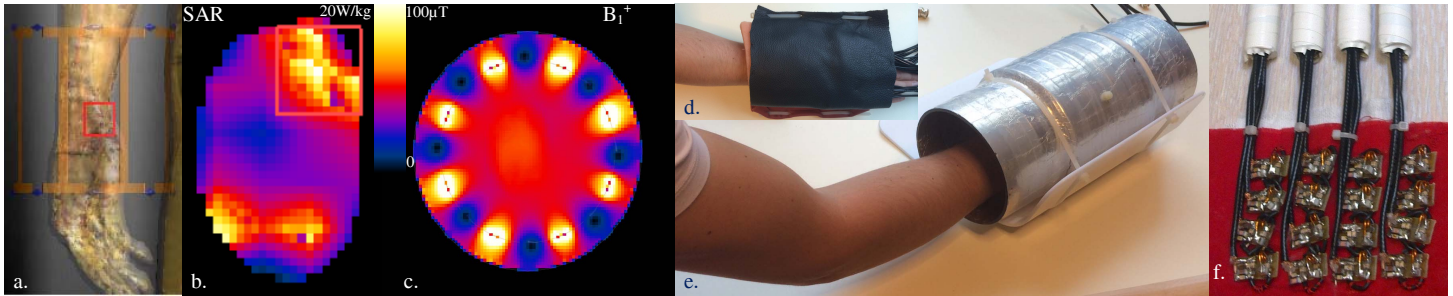


Fig1. RF coil setup for the human wrist at 7T. SAR (b) and B1+ (c) simulations of the coil setup loaded with a human wrist (a) demonstrate high B1+ efficiency per unit of maximum local SAR. The shielded quadrature birdcage transmitter can remain small in size (e), while providing space for a 32 channel receiver array (d) at high element density (f).

Methods

A detunable 8-rod birdcage was designed (MR coils BV) with an inner diameter of 100 mm and a shield of 140 mm and extended with reduced diameter (Fig 1e) and interfaced to a 7T MRI system (Philips). The B1+ performance and SAR was simulated using a wrist model in SEMCAD. $T_{1\rho}$ -mapping was performed using a 3D, $T_{1\rho}$ -prepared, single-shot gradient echo sequence. Four images with different spin-lock preparation times with an amplitude of $\gamma B1=833$ Hz were acquired (SL = 0, 12, 24, 48 ms). Bandwidth/pixel = 253 Hz, TE/TR = 3.2/7.2 ms, resolution = 0.5 x 0.5 x 0.5 mm³, FOV = 80 x 80 x 45 mm³, flip angle = 8 degrees, 2 shots, 2 averages, shot interval = 3500 ms, and 8-fold SENSE. A high resolution anatomical image was acquired using a T_2 -weighted spin echo sequence (TE/TR = 45/5000 ms, resolution = 0.25 x 0.25 mm, slice thickness = 1 mm, FOV = 80 x 80). $T_{1\rho}$ -maps were calculated by pixelwise fitting of an exponential decay function. One healthy volunteer, aged 23 years, was scanned in supine position, with the coil around the right wrist positioned alongside the body. The outer diameter of the shielded wrist coil was small enough to allow this position while in the bore of the MRI.

Results

The maximum B1+ that can be obtained is 50 μ T when connected to a 4kW RF amplifier. Analyses of measured B1+ maps demonstrate a non-uniformity of only 10% over the FOV of the $T_{1\rho}$ sequence. The local SAR limit of 20W/kg is reached with an effective B1+ of 4.9 μ T (Fig 1b), easily facilitating a strong spinlock field of 20 μ T. The 4 by 2 fold SENSE acceleration that can be accomplished with the high dense receiver array² enabled an isotropic spatial resolution of 0.5mm within a single $T_{1\rho}$ scan of 7 minutes (Fig 2). There were no movement artefacts.

Conclusion and discussion

While $T_{1\rho}$ sequences are known for their high SAR and B1+ field demands, here we demonstrate that uncompromised $T_{1\rho}$ imaging can be obtained at 7T with a SAR optimised RF coil setup. Combined with a high density receiver array, quantified $T_{1\rho}$ images of the wrist can be obtained at high spatial resolution of 0.5 mm isotropically within acceptable scantimes.

References 1. Menezes et al. *MRM*. 51, 503–9 (2004). 2. Petridou et al. *NMR Biomed*. 2013 Jan;26(1):65-73

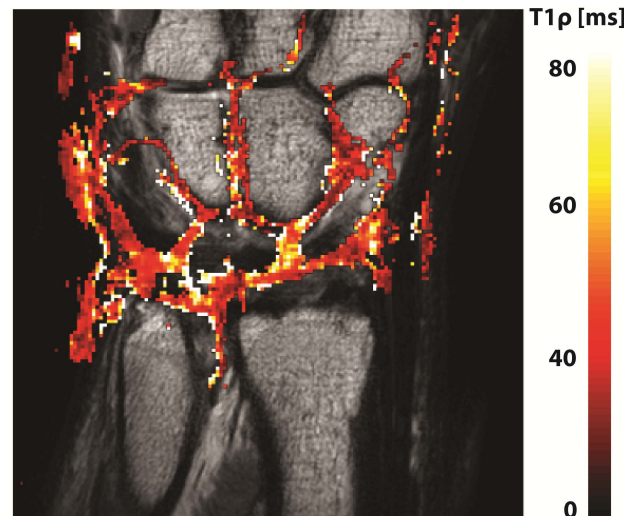


Fig2. Quantitative $T_{1\rho}$ image superimposed on a high resolution T_2 weighted MRI of the human wrist, coronal view of a right. The ultra high resolution at 0.5 mm provides detailed spatial information of $T_{1\rho}$ required for the thin cartilage within the wrist.