

## Magnetic Resonance Imaging Findings in a Dual Taper, Modular Total Hip Arthroplasty

Matthew F. Koff<sup>1</sup>, Stephanie L. Gold<sup>1</sup>, Brett Lurie<sup>1</sup>, Danyal H. Nawabi<sup>1</sup>, Geoffrey Westrich<sup>1</sup>, and Hollis G. Potter<sup>1</sup>

<sup>1</sup>Hospital for Special Surgery, New York, NY, United States

**Target Audience:** Clinician scientists, radiologists, and orthopaedic surgeons with an interest in adverse reactions to orthopaedic implants and the clinical application of metal susceptibility reduction pulse sequences.

**Purpose:** In the past two decades, modularity at the head-neck junction in total hip arthroplasty (THA) has demonstrated excellent safety and efficacy<sup>1</sup>. With the introduction of an additional modular connection at the neck-stem junction, these implants offered surgeons greater intra-operative flexibility, permitting patient specific selections of offset, version and length. Despite the benefits, these newer modular implants have been associated with failure due to neck breakage, neck-stem dissociation and most recently an adverse local tissue reaction (ALTR) leading to fretting and corrosion. ALTRs are associated with catastrophic local tissue destruction and subsequently higher complication rates after revision arthroplasty<sup>2</sup>. Therefore, early detection and prompt revision are crucial. Magnetic resonance imaging (MRI) has been used to non-invasively identify a failing hip implant, identifying the presence of ALTR in both painful and asymptomatic hips. While the appearance of ALTR on MRI in metal-on-metal arthroplasty was previously described<sup>2</sup>, no study to date has investigated the imaging appearance of ALTR in modular arthroplasty systems. The goal of this study was to: 1) identify the MR imaging findings characteristic of a failing dual taper THA system and 2) identify the MR imaging findings that are most indicative of an adverse local tissue reaction, as determined by histological analysis and intra-operative tissue damage scores.

**Methods:** This was an IRB approved retrospective study of 106 consecutive patients (124 hips) with a recalled dual taper modular hip arthroplasty system who underwent MRI using a modified protocol including MAVRIC-SL. The MR images were evaluated for the presence and type of synovitis, synovial thickness, synovial volume, low signal intensity deposits, soft tissue edema, pseudocapsular dehiscence, osteolysis, neurovascular compromise, and lymphadenopathy. 63 patients (66 hips) underwent revision arthroplasty with intraoperative assessment by single surgeon and tissue biopsy with review by single pathologist. Intra-operative tissue samples were analyzed and scored using Campbell's aseptic lymphocyte-dominated vasculitis-associated lesion (ALVAL) score<sup>3</sup>. Wilcoxon rank sum tests were performed to detect differences of measured variables between no ALVAL (score <5) and the presence of ALVAL (score ≥5). Spearman correlation coefficients were determined between ALVAL scores, MR variables and implant design specifications (SAS V9.3, Cary NC).

**Results:** There were 62 symptomatic and 62 asymptomatic hips. While 37/62 (60%) of the symptomatic hips had a moderate to severe ALTR, only 8/62 (13%) of the asymptomatic hips had moderate to severe ALTR. In the revision group (23 males, 43 females; mean age 64.5Y), 50/63 (79%) had synovitis, with a mixed or solid component in 40/66 (61%). The mean maximum synovial thickness/wall lining was 10.3 mm (range: 2-22 mm). In patients with synovitis, the volume was determined using a previously documented segmentation technique<sup>4,5</sup>. Among the 52 hips with synovitis, the mean synovial volume was 100,527 mm<sup>3</sup>. While only 20 hips (37%) had low signal intensity deposits, 41 hips (76%) had dehiscence of the pseudocapsule. The presence of osteolysis was rare in this cohort. Synovial thickness was positively correlated with the ALVAL score ( $\rho = 0.734$ ,  $p < 0.0003$ ) and with neck lengths of greater than 30 mm ( $p = 0.0032$ ). Pre-operative serum ion levels did not correlate with the ALVAL score.

**Discussion:** This study used MRI to evaluate patients with a dual taper modular THA, identifying the imaging findings that are most indicative of an ALTR as defined by histologic grading and intra-operative damage scores. As was identified in a previous metal-on-metal arthroplasty cohort<sup>2</sup>, synovial thickness is highly correlated with a diagnosis of ALVAL in patients with a modular head-neck and neck-stem implant. The positive correlation between synovial thickness and neck lengths of greater than 30 mm indicates that the larger moment arm at the neck-stem taper created with a longer neck may increase local fretting and the production of corrosion products, leading to increased catastrophic local tissue destruction.

**Conclusion:** Newer imaging techniques in MRI have improved the visualization of the soft tissue surrounding metallic hip arthroplasty, making modified MRI the modality of choice to predict the severity of an adverse tissue reaction. Sequences should be chosen that allow direct measurement of synovial/wall thickness. This technique, with its optimal soft tissue contrast, is especially important for screening patients with recalled implants. Given the poor survivorship (76.6% at 2 years) of the cobalt-chrome on titanium alloy modular neck-stem that was studied in this cohort, MRI should be used to promptly identify a failing hip, helping guide surgical management in patients with ALTR.

**References:** 1. Le D, Smith K, Tanzer D, et al. Modular femoral sleeve and stem implant provides long-term total hip survivorship. *Clin Orthop Relat Res* 2011;469:2:508. 2. Nawabi DH, Gold S, Lyman S, et al. MRI Predicts ALVAL and Tissue Damage in Metal-on-Metal Hip Arthroplasty. *Clin Orthop Relat Res* 2013. 3. Campbell P, Ebramzadeh E, Nelson S, et al. Histological features of pseudotumor-like tissues from metal-on-metal hips. *Clin Orthop Relat Res* 2010;468:2:2321. 4. Potter HG, Nestor BJ, Sofka CM, et al. Magnetic resonance imaging after total hip arthroplasty: evaluation of periprosthetic soft tissue. *J Bone Joint Surg Am* 2004;86-A:9:1947. 5. Walde TA, Weiland DE, Leung SB, et al. Comparison of CT, MRI, and radiographs in assessing pelvic osteolysis: a cadaveric study. *Clin Orthop Relat Res* 2005;437:138.

**Acknowledgements:** Institutional research support was provided by General Electric Healthcare.

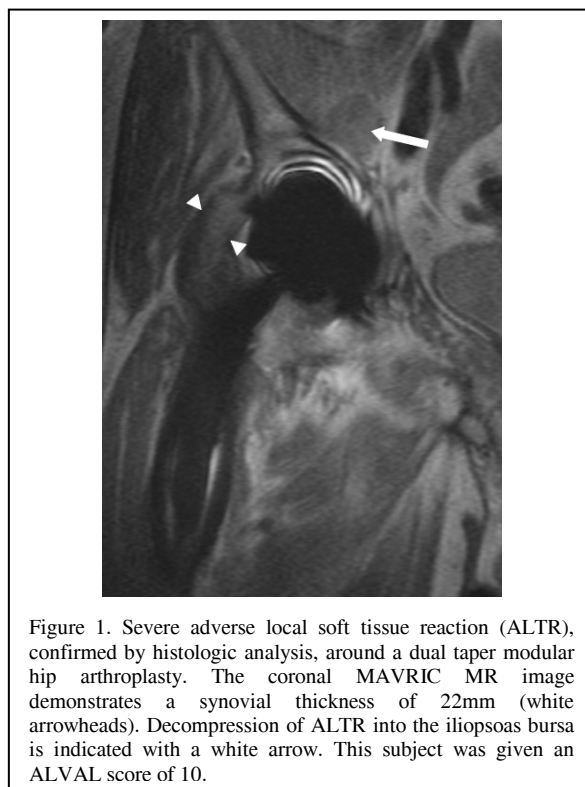


Figure 1. Severe adverse local soft tissue reaction (ALTR), confirmed by histologic analysis, around a dual taper modular hip arthroplasty. The coronal MAVRIC MR image demonstrates a synovial thickness of 22mm (white arrowheads). Decompression of ALTR into the iliopsoas bursa is indicated with a white arrow. This subject was given an ALVAL score of 10.