

## Assessment of inflammatory Component in the Mono-Iodoacetate (MIA) Model of Osteoarthritis by MRI

Thomas Kaulisch<sup>1</sup>, Laura Corradini<sup>2</sup>, and Detlef Stiller<sup>3</sup>

<sup>1</sup>Target Discovery Research, Boehringer Ingelheim Pharma GmbH & Co. KG, Biberach, Baden-Württemberg, Germany, <sup>2</sup>CNS Diseases Research, Boehringer Ingelheim Pharma GmbH & Co. KG, Baden-Württemberg, Germany, <sup>3</sup>Target Discovery Research, Boehringer Ingelheim Pharma GmbH & Co. KG, Baden-Württemberg, Germany

### Introduction

Osteoarthritis (OA) is a chronic, degenerative joint disease, characterized by the gradual loss of articular cartilage and joint pain. The Mono-Iodoacetate (MIA) model is an attractive tool for testing novel compounds at different stages of progressive OA development. So far the pharmacological profile of traditional analgesics has been characterized in the MIA model in rats by assessing the weight-bearing deficit and changes in pain-like behaviour. The MIA model has an inflammatory component which may not be reflected by weight-bearing deficit.

In two experiments we characterize the inflammatory component by firstly assessing the size of oedema (synovitis) which developed after intra-articular application of MIA in rats by volumetric MRI. Secondly we address the extravasation of contrast agent into the sylvian cavity as a surrogate for vessel leakage by DCE-MRI. In both cases the effect of treatment with the selective COX-2 inhibitor (Celecoxib) was investigated.

### Methods

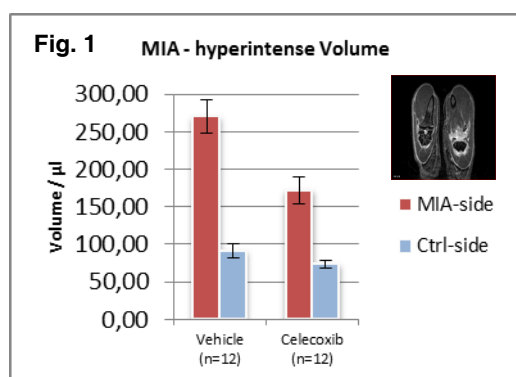
**MRI:** MRI data were acquired on a PharmaScan 70/16 scanner (Bruker BioSpin, Ettlingen, Germany) operating at 7 Tesla (300 MHz <sup>1</sup>H-Resonance). Animals were anaesthetized through continuous inhalation of 1.5-1.7% isoflurane (in 70:30 N<sub>2</sub>O:O<sub>2</sub>) and placed in the supine position. Knees of the animals were positioned in the centre of a 4-element phased-array volume coil (Rapid Biomedical, Würzburg, Germany).

**Acute MIA model – volumetry:** Male Wistar rats (200-250g, Charles River) were placed in an anaesthetic chamber and anaesthetised with a 2% isoflurane O<sub>2</sub> mixture. Knee joints of rats were treated with a single intra-articular injection of sodium iodoacetate (1 mg / 25µl) through the patella ligament. The same day after MIA application animals received either treatment with Celecoxib (30 mg/kg p.o. bid) or vehicle. On day two of treatment animals underwent a static MRI examination (FLASH3D; TE/TR = 3.7/11.0 ms; flip 15 DEG, FOV 5x5x5 cm<sup>3</sup>, 256x256x128, scan time approx. 4:30 min). For contrast enhancement 0.3 mmol/kg Gd-DTPA (Magnevist, Bayer, Germany) was administered via tail vein 5 minutes before data collection. Image data were processed by region-grow algorithm using a custom-made image analysis tool based on the IDL language (Exelis, Germany). Treatment and analysis were done in double-blinded design.

**Chronic MIA model – DCE-MRI:** After MIA-application (3 mg) animals received a single dose of α-NGF (10 mg/kg i.v.) followed by a chronic pain treatment with Celecoxib (30 mg/kg p.o. bid). For different groups treatment was started at day 3 or 14 and continued until day 24 resulting in a treatment period of 21 and 10 days respectively. A MIA control group with no treatment was included. Animals were scanned with a DCE-MRI type protocol at days 0, 3, 7, 14, and 24 (FLASH; TE/TR = 2.9/34.6 ms; flip 15 DEG, FOV 5x5 cm<sup>2</sup>, 1.5 mm slice thickness; 2 averages, 2 packages with 2 slices each, total scan time approx. 10:20 min). Contrast agent was applied after 50 seconds baseline scan (0.3 mmol/kg Gd-DTPA i.v.). Dynamic data were taken from an ROI (s.fig. 1) within the joint cavity and normalized to relative signal intensity change from baseline.

**Results & Conclusion:** MRI volumetry yields hyperintense volume which can clearly distinguish between treated and non-treated animals with an effect size of approximately 100 µl in acute MIA-model (fig. 1). In chronic MIA model DCE-MRI reveals different grades of extravasation dependent on starting point and length of chronic pain treatment (fig. 2).

Results suggest that both static and dynamic MRI can be used to assess treatment efficacy in the inflammatory edema symptom of the MIA-model. This can be useful to complement scorings based on pain-based behavioral data like weight-bearing.



### References

[1] Janusz MJ et al., Osteoarthrosi Cartilage 2001; 9, 751-760 [2] Pomonis JD et al., Pain 2005; 114, 339-346 [3] Chaplan SR et al., J NeurosciMethods 1994; 53 55-63 [4] Fernihough J et al., Pain 2004; 112, 83-93

