

Evaluation of new software for cartilage thickness estimation in knee MR images with severe metallic artefact

Ryan Nazareth¹, Peter Cashman², Pauline Parlier², Annie Papadaki¹, Lesley Honeyfield¹, Keshthra Satchithananda¹, Donald McRobbie¹, and Fiona Watt³

¹Imperial College Healthcare NHS Trust, London, United Kingdom, ²Imperial College London, London, United Kingdom, ³Kennedy Institute of Rheumatology, Oxford, United Kingdom

Purpose

Cartilage morphology change is an important biomarker for the progression of osteoarthritis. Individuals at our centre have been recruited immediately after their knee injury and are being followed for 5 years. Monitoring cartilage change is desirable in those with knee injuries who are at high risk of early osteoarthritis. Many of these subjects have undergone knee surgery at baseline and their subsequent MR images contain artefacts due to the presence of metal implants. These can greatly complicate reliable segmentation of cartilage from images. Previous published works on automated methods for cartilage thickness estimation have described validation studies using images of near-perfect quality. Here we validate the reliability and accuracy of our semi-automated in-house software KneeSeg2, firstly using a custom made phantom to simulate the knee and secondly by measuring cartilage thickness from clinical images with severe metallic artefact.

Method

A phantom imitating knee geometry was first designed as two Perspex cylinders of known diameter, eccentrically attached to each other. Perspex rods positioned on the outer cylinder surface provide angular landmarks every 30° to measure cartilage thickness (Figure 1A). Both cavities were filled with appropriate contrast materials to mimic the MR properties of bone and cartilage. A titanium surgical screw was also added to simulate a surgically repaired knee and generate metal artefact in the images (Figure 1B). Images of the phantom were acquired on a Siemens 3T Magnetom Verio MR scanner with an 8 channel knee coil using a Double Echo Steady State sequence¹. The following protocol was used: FOV 159-170mm, matrix 480 x 512, flip angle 25 degrees, bandwidth 222 kHz, slice thickness 0.65mm, TR/TE 14.84/5.04 msec. Sagittal knee images with metal artifact (Figure 1D) were also acquired from a volunteer on the same scanner using the same sequence and protocol as above. The images were analysed offline using in-house software KneeSeg2, an updated version of that previously published in 2002². Median and Sobel filters are applied to remove noise and produce a gradient magnitude image respectively. The latter is adaptively thresholded to produce a binary edge image. Metal artefact within the bone is removed using the bone artefact mask (BAM), an adaptive contour manually preset by the user, which surrounds and nulls the metal artefact but does not impinge on the bone-cartilage boundary. The final stage of the segmentation process involves conventional closing and dilation of the binary bone region to produce a broad white outer shell around the bone. This is used as a mask to pre-segment the cartilage from the original source image (Figure 1C and E). The final segmented cartilage thickness is computed by searching outwards from a search origin positioned in the centre of the bone until the inner cartilage boundary is reached and then proceeding in a direction normal to the bone-cartilage interface until the outer cartilage boundary is reached. This procedure is repeated automatically for all slices in the volume and a cartilage thickness map is generated using cylindrical projection. Siemens Magnetom Verio Syngo MR B17 software was used to carry out a number of manual measurements on the phantom and clinical data sets. Bland-Altman analysis was used to quantify the agreement between the manual and automated measurements at the same locations³. Results from clinical data sets with and without metal artefact were also compared. To test objectivity, the experiments were repeated using different operators.

Results

At our centre, the clinically acceptable thresholds for the bias and limits of agreement with such measurements are 0.2mm and 1mm respectively. In both the phantom and clinical data sets, there was good agreement between the manual and automated measurements except for some slices where the metal artefact impinged on to the cartilage (yellow points in Figure 2A and B). Here, the measurements for the clinical data set in particular severely overestimated the cartilage thickness around the artefact zone compared to the results without artefact. Provided the operators preset the BAM consistently, KneeSeg2 gave identical results over time within and between operators.

Conclusions

The KneeSeg2 program successfully segmented the cartilage boundaries on clinical images containing metallic artefact, provided the artefact was all contained within the bone. In comparison with the manual ruler tools routinely used by radiographers, KneeSeg2 offered the same level of accuracy and precision but a substantial reduction in time, robustness to changes in the display contrast and brightness, good inter-observer agreement and repeatability. Future work under consideration would be to include the gel phantom as part of a quality assurance programme, monitoring cartilage thickness change using KneeSeg2 in prospective interval scans of participants over a number of years. The effect of adjusting the MR acquisition parameters on the artefact patterns will also be explored.

References

[1] F. Eckstein et al. Ann Rheum Dis 2006, 65(4):433-441. [2] P.Cashman et al. IEEE Trans Nanobioscience 2002;1(1): 42-51. [3] J.Bland et al. Lancet.1986;1(8476): 307-10

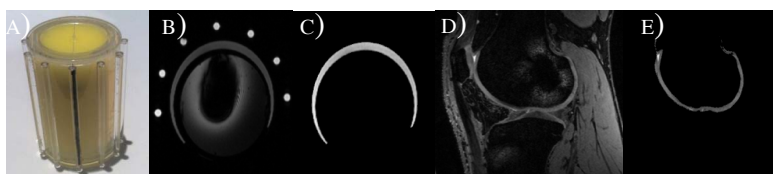


Figure 1: A) Cylindrical phantom simulating knee geometry. B) Image of the phantom showing metal artefact within the bone; also seven angular markers provided for precise location of the cartilage measurements. C) Segmented phantom cartilage using the KneeSeg2 software. D) Sagittal image of patient knee with severe metal artefact within the bone of the femur. E) Cartilage segmentation using KneeSeg2 after applying the special bone artefact mask.

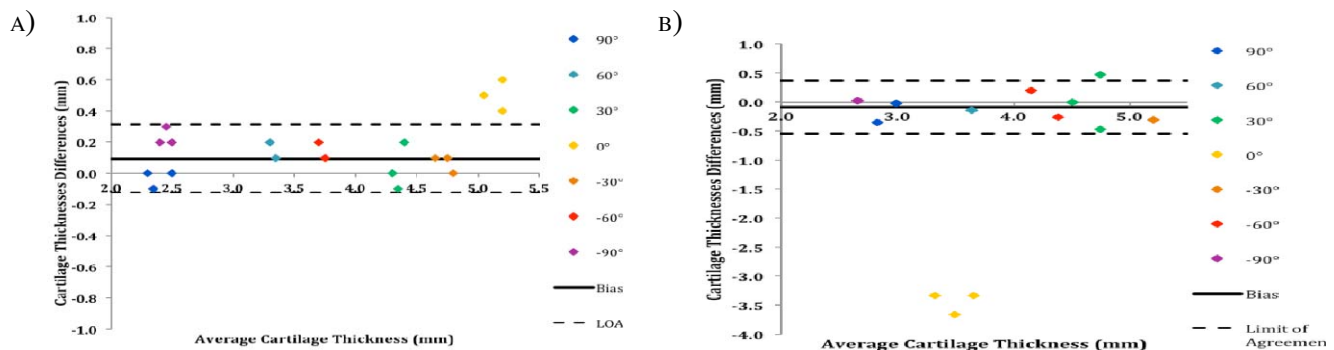


Figure 2: Bland-Altman comparison of manual versus automated cartilage thickness at different angular landmarks in A) phantom B) clinical data sets. All measurements are within the limits of agreement except for the yellow points where the intrusive artefact is dominant (see text).