

## Micro-imaging of finger tendons in vivo using a dedicated solenoidal finger coil at 7 T

Elmar Laistler<sup>1,2</sup>, Andre Kuehne<sup>1,2</sup>, Sigrun Goluch<sup>1,2</sup>, Barbara Dymerska<sup>2</sup>, Jürgen Sieg<sup>1,2</sup>, and Ewald Moser<sup>1,2</sup>

<sup>1</sup>Center for Medical Physics and Biomedical Engineering, Medical University of Vienna, Vienna, Austria, <sup>2</sup>MR Center of Excellence, Medical University of Vienna, Vienna, Austria

**Target Audience:** Researchers who are interested in ultra-high resolution MSK and RF coils.

**Purpose:** To demonstrate the potential of a dedicated finger coil for ultra-high resolution MSK applications.

### Introduction

Injuries of the finger tendons are common, especially among sport athletes [1,2], particularly climbers. Due to the small structures in the finger and the lack of sensitivity for sufficient spatial resolution of MR images in reasonable measurement time, MRI has not been used routinely for diagnosis, although a few studies have shown MR data of fingers [3–5]. By combining ultra-high field strength and a dedicated coil optimized for finger imaging, these limitations can be overcome.

### Methods

**Hardware:** Measurements were performed on a 7 T whole body MR scanner (Siemens Magnetom, Erlangen, Germany) using a custom-built transceive RF coil optimized for sensitivity and homogeneity in the finger (RSA, CMPBME, MedUni Vienna, Austria). The coil consists of a solenoid ( $d = 28$  mm,  $L = 55$  mm) with 3 irregularly spaced windings to enlarge the homogeneous volume along the coil axis [6].

**SAR calculation:** To ensure patient safety, SAR distribution in the finger was calculated using XFDTD (Remcom, State College, PA, USA) and SimOpTx (RSA, CMPBME, MedUni Vienna, Austria). Due to the very small exposed volume, the coil was defined as a local transmit coil.

**Subjects and sequences:** The index finger of a healthy volunteer (male, 32 years) was measured. A T1 weighted MPRAGE sequence (TR/TE/TI = 2730/6.71/1700 ms) with  $195 \times 195 \times 200 \mu\text{m}^3$  resolution, scan time 8 min 45 s, and a 2D TSE (TR/TE = 7450/26 ms, turbo-factor 7) with  $78 \times 58 \mu\text{m}^2$  in plane resolution and a slice thickness of  $500 \mu\text{m}$  at a scan time of 6 min 6 s, were used. Images were post-processed in Syngo (Siemens Medical Solutions, Erlangen, Germany) to produce sagittal, axial, and quasi-coronal curved slices along the flexor digitorum tendons.

### Results

Figure 1 shows different slices and reformattings of the MPRAGE sequence data set. In Fig. 1a, the flexor digitorum tendons can be readily observed in a sagittal view through the center of the finger. The positions where the flexor digitorum superficialis/profundus tendon is attached to the distal/middle phalanx, respectively, are clearly visible (green arrows). Figs. 1b and 1c show a cross-section of the flexor tendons, revealing its internal structure. Figs. 1d and 1e display a curved slice along the flexor digitorum profundus tendon with the internal structure of the tendon visible. Fig. 2 displays an axial slice of the 2D TSE sequence with even higher in-plane resolution, approximately at the center of the middle phalanx, showing cross-sections of the flexor digitorum profundus and the extensor digitorum tendons (red and blue arrows).

### Discussion

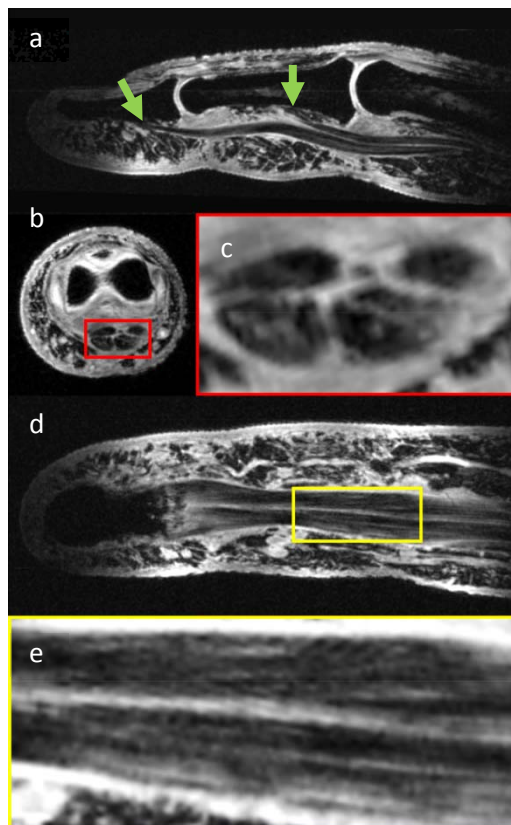
The sensitivity of the 7 T finger coil used in this study enables the investigation of delicate structures in the human finger in vivo at sufficient SNR in acceptable measurement times, i.e., well below 10 min. The sequences optimized for visualizing tendons with this coil allow for depiction even of the internal structure of the flexor digitorum tendons. The coil can, therefore, be used to assess injuries of the finger tendons. With the respectively optimized sequence parameters, also other anatomical parts and pathologies in the finger could be investigated, including but not limited to cartilage, vessels, and nerves.

### Conclusion

A highly sensitive dedicated RF coil for finger micro-imaging at 7 T is presented, suited to investigate tendons and other anatomical structures in the human finger in vivo with unprecedented spatial resolution and contrast.

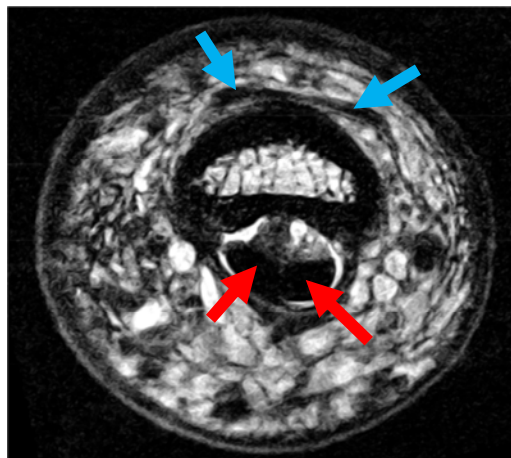
### References

- [1] Yeh, Hand Clin 28, 425-30, 2012
- [2] Leggit, Am Fam Phys 73, 810-16, 2006
- [3] Clavero, RadioGraphics 22, 237-56, 2002
- [4] Kwok, JMRI 31, 240-7, 2010
- [5] Langner, Clin Anat 26, 719-27, 2013
- [6] Laistler, ESMRMB 2012, #433



**Fig. 1** T1 MPRAGE,  $195 \times 195 \mu\text{m}^2$ , 128 slices/ $200 \mu\text{m}$  thick, TA = 8 min 45 s, with fat saturation.

a) sagittal slice through the index finger, b) axial slice at position of the proximal interphalangeal joint, c) magnification of flexor digitorum tendon cross-section, d) curved, quasi-coronal slice along flexor digitorum tendons, e) magnification.



**Fig. 2** 2D axial TSE,  $78 \times 58 \mu\text{m}^2$ , 60 slices/ $500 \mu\text{m}$  thick, TA = 6 min 6 s. Red arrows: flexor digitorum profundus tendons, blue arrows: extensor digitorum tendons.