

Metabolomic Imaging for Human Prostate Cancer Detection using MR Spectroscopy at 7-T

Romy Langhammer^{1,2}, Leo L. Cheng¹, Johannes Nowak³, Shulin Wu¹, W. Scott McDougal¹, Chin-Lee Wu¹, and Eva M. Ratai¹

¹Massachusetts General Hospital, Harvard Medical School, Boston, Massachusetts, United States, ²Institute of Radiology, Department for Neuroradiology, University Hospital Wuerzburg, Wuerzburg, Bavaria, Germany, ³Institute of Radiology, Department for Neuroradiology, University Hospital Wuerzburg, Wuerzburg, Bavaria, Germany

Target audience: With an estimated 238,590 new cases in 2013, prostate cancer (PCa) is the most frequently diagnosed malignancy and the second leading cause of cancer death for men in the United States¹. As the clinically dominating screening tool, the prostate specific antigen (PSA) serum test, is prostate- but not cancer-specific, elevations in PSA often lead to random biopsy due to the lack of imaging guidance². False negatives, also known as histology sampling errors, commonly occur, due to the tendency of early stage PCa to spread heterogeneously³. Therefore, a more reliable diagnosis system is needed - ideally with an *in-vivo* approach - that could allow for the detection of PCa lesions before biopsy, and potentially predict tumor stage and malignant potential before radical treatment.

Purpose: The purpose of the present study is to develop a diagnostic test for PCa, with *in vivo* potential, by creating and analyzing metabolomic maps (including 36 different metabolic regions) using magnetic resonance spectroscopy (MRS) at 7T. To test the functionality and reliability of this system, also known as "metabolomic imaging", the results are compared with the histopathology findings.

Methods: Thirty whole prostates, removed from prostatectomies and with biopsy-proven PCa, were analyzed with a 7-Tesla human MRI scanner. The MRS of the middle transverse cross-sectional plane, consisting of 16x16 voxels and with a thickness of 3mm, was recorded for each specimen. After MRS, the samples were cut and analyzed with traditional histopathology. For the processing of the spectral data, an in-house MATLAB-based program was used, which automates part of the procedure. After manual correction of the phase and baseline for all spectra, the program performs an automatic curve-fitting with Lorentzian-Gaussian line-shapes, and the integral for each individual peak for all spectra is calculated, evaluated and combined with loading factors, in order to obtain cancer predictive values. The loading factors were determined previously from prostate tissue spectroscopy with a 14-Tesla spectrometer, and they create a metabolomic cancer profile by weighting the different peak intensities for each metabolite³. In order to compare the MRS suspicious regions with the histopathology - especially in terms of location - the histological and MRI middle slides were overlaid (Figure 1).

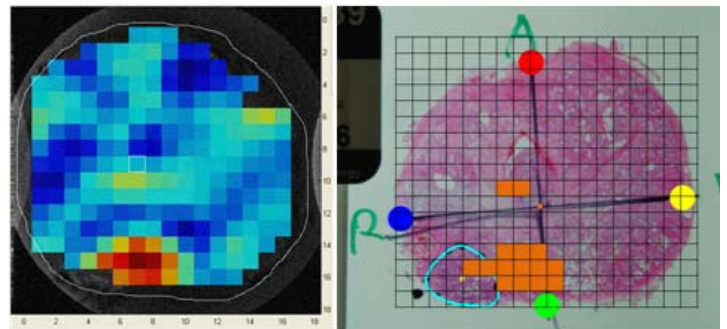


Figure 1: The MRS/MRI voxel grid (left) and the histological slide (right) were overlaid, and the positions of the histological tumor lesions (circled in blue) and MRS suspicious regions (filled in orange, right) were compared.

Results: In 61% of the samples, MRS detected cancer lesions in the same locations as were identified in the histopathology analysis. The histological cancer regions that were not detected by MRS, had significantly lower tumor volumes (p-value=0.023) than those that were detected (Figure 2, right). Furthermore, a "malignancy index" (MI), calculated for each region by multiplying the metabolomic profile value of the voxels by the voxel sizes, can differentiate between MRS suspicious regions that are cancerous and those that are benign (p-value=0.002, Figure 2, left). Gleason grade and tumor stage (of TNM classification) did not correlate with the MI. Further analysis is currently being conducted in the laboratory.

Discussion and conclusions: Metabolomic imaging using MRI/MRS seems to be a promising non-invasive system that may be able to guide biopsy and therefore prevent false negatives in prostate diagnosis. However, further modifications need to be done, in order to raise the sensitivity of the system. For example the criteria for the voxel values and lesion sizes, that are considered as MRS cancer suspicious, as well as the metabolomic cancer profile itself need to be reviewed. Subsequently, the system has the potential to be used as an independent, non-invasive tool for the detection, monitoring and diagnosis of PCa.

References:

¹ American Cancer Society. Cancer facts & figures. 2013

² National Cancer Institute. Fact sheet: Prostate-Specific Antigen (PSA) Test. 2012

³ L.L. Cheng, M.A. Burns, J.L. Taylor, W. He, E.F. Halpern, W.S. McDougal, C.-L. Wu: Metabolic Characterization of Human Prostate Cancer with Tissue Magnetic Resonance Spectroscopy. Cancer Research, 65: (8), April 15, 2005

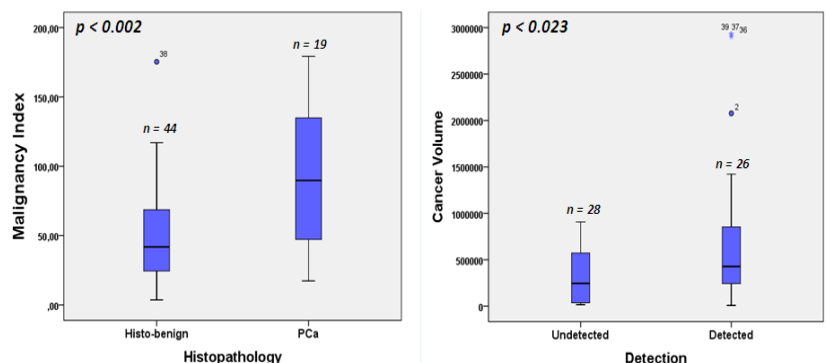


Figure 2: Metabolomic Imaging: results from 30 consecutive prostatectomy cases