

# Type Discrimination of Calcifications using High-pass Filtered Phase Images of Multiple Fast Field Echo Sequence

Katsuhiro Kida<sup>1</sup>, Sachiko Goto<sup>2</sup>, Tsutomu Kajitani<sup>1</sup>, and Yoshiharu Azuma<sup>2</sup>

<sup>1</sup>Department of Radiology, Japanese Red Cross Okayama Hospital, Okayama-shi, Okayama, Japan, <sup>2</sup>Faculty of Health Sciences, Graduate School of Health Sciences, Okayama University, Okayama-shi, Okayama, Japan

## Purpose:

In mammography, the presence of microcalcifications in breast tissues is of great importance since microcalcifications are mammographic characteristics of early breast cancer.<sup>1, 2</sup> The microcalcifications in breast disease have two distinct types, calcium oxalate ( $\text{CaC}_2\text{O}_4 \cdot 2\text{H}_2\text{O}$ ) and phosphate ( $\text{Ca}_{10}(\text{PO}_4)_6 \cdot \text{H}_2\text{O}$ ).<sup>3</sup> It has been reported that microcalcifications with calcium oxalate were found only in benign cysts, whereas microcalcifications with calcium phosphate were associated with benign or malignant lesions.<sup>3</sup> We previously reported the detection of clam shell (as simulating calcification) using high-pass filtered phase images of MRI.<sup>4</sup> In this study, we furthermore discriminated the two types of calcifications of known components.

## Methods:

A cup shaped gel phantom, containing calcium materials of known components which are 10 kidney stones of calcium oxalate, 5 kidney stones of calcium phosphate, 5 teeth and 5 chinks, was made to simulate calcification in the breast. Five teeth were employed since its enamel has a high content of calcium phosphate. Our work was performed on the 3.0 T MR system (Achieva 3.0T TX, Philips). Five phase images with different echo times (TE) were obtained using a 3D multi-gradient-echo (known as multiple fast field echo or m-FFE) sequence. Five magnitude images were also obtained at the same time. Other acquisition details were: repetition time (TR)=26 msec,  $\text{TE}_1/\text{TE}_2/\text{TE}_3/\text{TE}_4/\text{TE}_5=4.6/9.2/13.6/18.2/22.8$  msec, flip angle=25 deg, matrix size=256x256, field of view (FOV)=256, slice thickness=1 mm. The obtained phase images were caused "wrapping" whenever a measured phase signal is defined only in the range  $[-\pi, \pi]$ .<sup>5</sup> The phase unwrapping was calculated by using PRELUDE (<http://www.fmrib.ox.ac.uk/fsl/>). Furthermore, the unwrapped phase image contains the static field inhomogeneity effects. We removed the static field inhomogeneity effects using high-pass filter. Those processes were performed with ImageJ 1.38x (National Institutes of Health, USA). On the high-pass filtered phase images, phase values of calcium oxalate, calcium phosphate and chalk were averaged.

## Results:

On the magnitude image, calcium oxalate, calcium phosphate and chalk appeared as hypointense areas, as shown in Fig. 1. On the other hand, calcium oxalate and calcium phosphate appeared as hyperintense areas on the high-pass filtered phase image. As shown in Fig. 2, the phase value of them became higher as TE became longer. The slope of linear approximation of the calcium oxalate was larger than the calcium phosphate. The phase value of chalk on the high-pass filtered phase image did not approximately have a change.

## Discussion:

Detection of calcium oxalate and calcium phosphate was possible by using high-pass filtered phase image. The phase value of chalk was almost zero. We think that its difference was the number of hydrogen and structure of calcium. Furthermore, we think that calcium phosphate and the calcium oxalate are distinguishable with the slope of linear approximation. Radi MJ reported<sup>3</sup>, microcalcifications with calcium oxalate were found only in benign cysts and were not associated with carcinoma or epithelial hyperplasia, whereas microcalcifications with calcium phosphate were associated with benign or malignant lesions. The discrimination between calcium oxalate and calcium phosphate is effective for clinical diagnosis of breast cancer. Usage of m-FFE was useful to shorten examination time.

**Conclusion:** We conclude that the calcium oxalate and the calcium phosphate are distinguishable with the slope of linear approximation of calcifications on high-pass filtered phase images. We believe that this method is useful for the discrimination between benign and malignant breast disease.

## References:

1. Fatemi-Ardekani A, Boylan C and Noseworthy MD. Identification of breast calcification using magnetic resonance imaging. *Amer. Assoc. Phys. Med.* 2009;36(12):5429-5436.
2. Brem RF, Hoffmeister JW, Zisman G, et al. A computer-aided detection system for the evaluation of breast cancer by mammographic appearance and lesion size. *Amer. Roent. Ray Soc.* 2005;184(3):893-896.
3. Radi MJ. Calcium oxalate crystals in breast biopsies. An overlooked form of microcalcification associated with benign breast disease. *Arch Pathol Lab Med.* 1989;113(12):1367-1369.
4. Kida K, Goto S, Kuwahara S. et al. Detection of Calcification using Magnetic Resonance phase imaging for Breast Cancer Screening. *In Proceedings of the SMRT 21th Annual Meeting.* 2012.
5. Rauscher A, Sedlacik J, Barth M. et al. Magnetic susceptibility-weighted MR phase imaging of the human brain. *AJNR. Amer. J. Neuroradiol.* 2005;26(4):736-742.




Fig.1. Magnitude image, phase image, unwrapped phase image and high-pass filtered phase image of gel phantom.

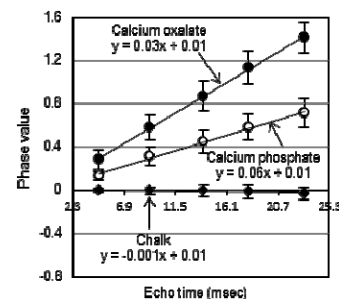


Fig.2. Phase value of calcium oxalate, calcium phosphate and chalk on high-pass filtered phase image as a function of TE.