

Multi Slice-Group Slice-Accelerated Breast Diffusion MR Imaging on 3T

Sinyeob Ahn¹, Himanshu Bhat¹, Dorota Wisner², Kawin Setsompop³, Thomas Benner⁴, Stephen Cauley³, Borjan Gagoski⁵, Bonnie Joe², Gerhard Laub¹, and Vibhas Deshpande¹

¹Siemens Healthcare, San Francisco, CA, United States, ²Radiology and Biomedical Engineering, UCSF, CA, United States, ³Radiology, MGH, MA, United States,

⁴Siemens Healthcare, Erlangen, Germany, ⁵Children's Hospital, Boston, MA, United States

Introduction

Breast diffusion MRI has been used to provide good lesion characterization using the apparent diffusion coefficient (ADC)^{1,2}. Breast diffusion imaging is typically practiced with an axial slice orientation and FOV of approximately 35~40 cm L-R. When a large FOV is used in an axial orientation, there may be significant B0 field inhomogeneity and nonlinearity in the readout direction (L-R) that can confound the EPI phase correction. If the phase correction is inaccurate, EPI images will show ghosting artifacts. To minimize the phase correction problem, a sagittal slice orientation may be a good alternative in which the readout direction is head-foot. Although this also exhibits B0 field inhomogeneity over a large FOV, its effects would be minimized by the limited receive field sensitivity of the breast coil in this direction. Since signal from inhomogeneous B0 field is minimized, the phase correction may be improved. However, the sagittal orientation requires a large amount of slice coverage and subsequently long scan time. In this paper, we propose a multiple slice group slice-accelerated sequence for sagittal bilateral breast diffusion imaging. This sequence is a modification of the recently developed multi-slice slice-accelerated EPI technique³, but better suited for a sagittal breast imaging application. It offers nearly identical image quality with almost half the scan time as compared to the standard bilateral sagittal diffusion imaging technique. The sequence exploits the uniqueness of anatomical geometry and the separation of the coil elements of the breast coil. This maximizes separation of the aliased images from slice-accelerated imaging, in addition to the blipped-Caipirinha inter-slice FOV shift along the phase-encode (PE) direction⁴.

Materials and Methods

Two patients were scanned on a wide-bore 3T Magnetom Verio (Siemens Medical Solutions) with a 16-channel breast coil (Hologic). A single shot (SS)-EPI sequence was used for acquiring the diffusion images, one with a standard and the other with the slice-accelerated technique (MB=2) for comparison. For the standard diffusion technique, only one breast was imaged. For the slice-accelerated technique, two slice groups were positioned, one group on the left breast and the other set on the right breast. Typical separation of the two slice groups was approximately 15 cm. The matching slice numbers in both groups (Fig. 1) were excited simultaneously using an optimized multiband RF pulse. The reference scan was acquired in one extra TR in the slice-accelerated sequence. The protocol parameters were as follows: FOV = 150x200 mm, matrix = 82x110 (resolution = 1.8x1.8x2.4 mm), 7/8 partial Fourier, GRAPPA 2, 1568 Hz/pix bandwidth, 3-scan trace (b=0 and 800 sec/mm²), PE direction: P-A, coronal posterior saturation. For standard EPI: TE/TR= 72/10000 msec, unilateral (39 slices for one breast only), 6 averages, total scan time= 4:30 min and for the slice-accelerated EPI: MB=2, slice separation as needed, TE/TR= 73/10000 msec, 78 slices (39 slices in each slice group), 5 averages, total scan time=4:29 min. For image assessment, data were reviewed by an experienced board-certified radiologist to evaluate the likeness of the slice-accelerated images as compared to the standard. Shim volume for the slice-accelerated sequence was set to cover the two slice groups and that for the standard EPI was set to cover one breast imaging volume.

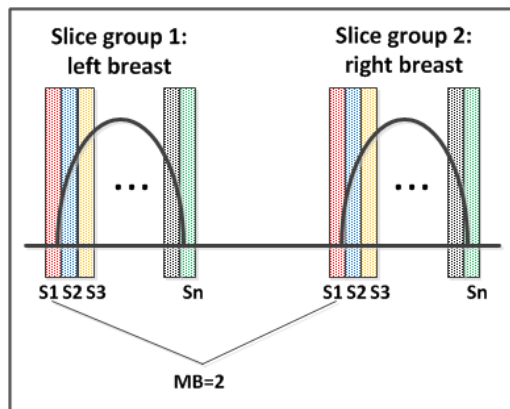


Figure 1. Two slice group slice-accelerated sagittal bilateral breast diffusion imaging

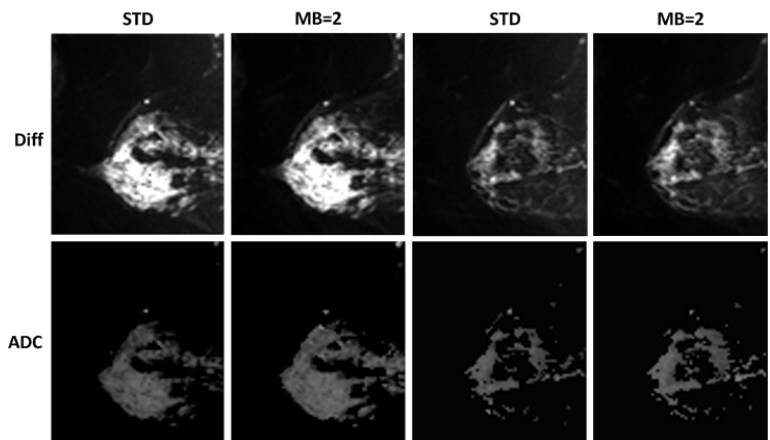


Figure 2. Image comparison between standard and slice-accelerated breast diffusion imaging techniques

Results

Fig. 2 shows the comparison of images from the two techniques. Slice-accelerated diffusion imaging produced nearly identical image quality as compared to the standard imaging technique. The scan times of the two sequences are almost identical, but the slice-accelerated scan has double the slice coverage of the standard scan (78 slices as compared to 39). Relative SNR of the standard diffusion imaging sequence was slightly higher than that of the slice-accelerated imaging sequence (STD: 71.5 vs. MB=2: 68.9 from 5 representative sagittal slices). Radiologist evaluated that the only appreciable difference between the two acquisition methods was a slight improvement in overall signal using the slice-accelerated technique and otherwise, image quality was rated identical.

Discussions and Conclusion

In this study, we present a multiple slice group, sagittal bilateral slice-accelerated diffusion imaging technique for improved breast diffusion image quality and reduced scan time. Scan time of the slice-accelerated technique (MB=2) is a little more than half that of the standard diffusion technique because of the additional calibration scan that is required for estimation of the coil sensitivities. The difference in the shim volumes between the standard scan (covering only one breast) and the slice-accelerated scan (covering both breasts) was found to have negligible effect on the image quality. In conclusion, the slice-accelerated sagittal bilateral breast diffusion imaging technique may be a viable tool for breast lesion characterization within reasonable scan time (<5 min).

References

- [1] Lo et al. J Comput Assist Tom 2009;33:63-69
- [2] El Khouli et al. Radiology 2010;256:64-73
- [3] Moeller et al. MRM 2010;63:1144-1153
- [4] Setsompop et al. MRM 2012;67:1210-1224