

VOLUMETRIC BREAST DENSITY QUANTIFICATION FROM 2D MAMMOGRAPHIES COMPARED WITH BREAST MRI

Camila Munoz¹, Dravna Razmilic², Maria E. Navarro², Paula Espinoza², Cristian Tejos¹, Pablo Irarrazaval¹, Sergio Uribe¹, and Marcelo E. Andia^{1,2}

¹Biomedical Imaging Center, Pontificia Universidad Catolica de Chile, Santiago, Region Metropolitana, Chile, ²Radiology Department, School of Medicine, Pontificia Universidad Catolica de Chile, Santiago, Region Metropolitana, Chile

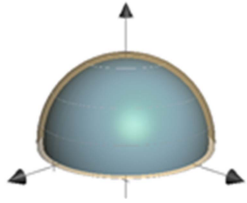


Figure 1: Representation of a hemi-spherical breast, with 80% of volumetric breast density. The radius difference between the two hemispheres is less than 7.5%

INTRODUCTION: Breast cancer is the most common invasive cancer in women and represents 16% of all female cancers worldwide. Early detection of this cancer by mammography has shown a significant impact on the reduction of mortality. In order to increase the sensitivity of breast cancer detection using mammography it has been proposed the breast density as a new independent risk factor. The estimation of breast density is currently conducted visually and non-quantitatively by radiologists, based on heavily post-processed X-ray images, with high inter and intra observer variability, and with results that do not have geometrical consistency [1]. For example, breast densities have been reported near 80%, which is highly impossible to occur, as shown in the diagram in Figure 1. Therefore, a quantitative approach is needed to reliably estimate the volumetric breast density.

PURPOSE: In this work, we propose a quantitative approach to estimate volumetric breast density, i.e. the fraction of the breast volume occupied by fibroglandular tissue. As mammograms are a simple, cheap and widely used exam, adding quantitative information will have a major impact. We designed a method to estimate volumetric breast density from mammogram, which is comparable to the measurement

obtained from 3D Breast MR.

METHODS: We used a clinical database from 11 exams, in patients with contemporaneous mammogram and breast MRI. For each technique we develop an algorithm to calculate the total breast volume and the fraction of volume occupied by fibroglandular tissue. Mammograms are a 2D representation of the breast volume, so a new patient-specific geometric model based on [2] was designed to represent the volume deformation of the breast during the acquisition. Using the volume reconstruction we adjust an x-ray decay model (Eq. 1) to estimate the volume of each group of tissue [3]. We use the raw-data mammogram data to adjust our model (Figure 2).

$$\frac{I(r)}{I_0} = e^{-\mu_{fat}\Delta x_{fat}(r) - \mu_{gland}\Delta x_{gland}(r)}$$
 (Eq. 1), where $I(r)$ is the intensity at a position r , $\Delta x_{fat}(r)$ and $\Delta x_{gland}(r)$ are the width of fat and glandular tissue at a position r , respectively. I_0 is an acquisition constant and μ_{fat} and μ_{gland} are decay constants.

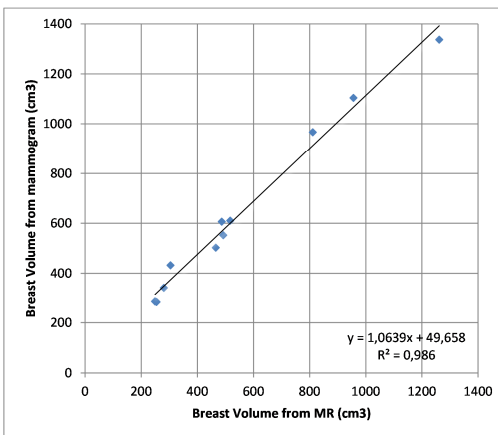


Figure 3: Breast volume obtained from both imaging techniques: MR in x-axis and mammogram in y-axis.

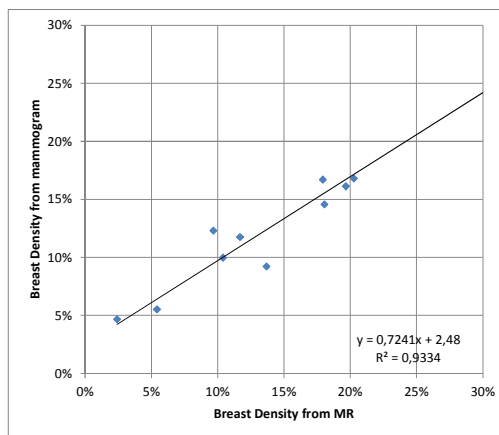
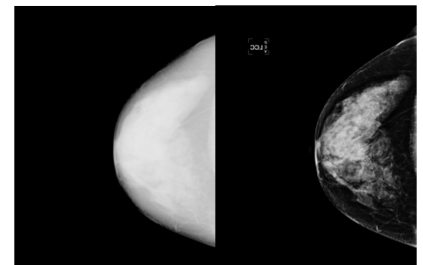


Figure 4: Breast density obtained from both imaging techniques: MR in x-axis and mammogram in y-axis

With the geometric model validated, and using the x-ray decay model, we estimate the breast density from mammograms. Compared with the breast density obtained from 3D MR images, we obtain a consistent under estimation with a strong correlation ($R^2=0.933$), so a correction factor can be included to match both techniques. This results suggests that the method developed to estimate breast density from mammograms can be used as a reliable measurement, compared to the same variable obtained from 3D MR images.

CONCLUSIONS: The analysis showed that our mammogram based method to estimate the breast density volumetrically has an excellent agreement with MR quantification. The main advantage of our method is that it used a simple, cheap and widely used 2D exam, to obtain a volumetric breast tissue characterization similar to that obtained with breast MRI.

REFERENCES: [1] Kopans, D. Radiology, 246(2), 2008. [2] van Engeland, S. et al . IEEE TMI, 25(3), 2006. [3] Byng, J.W et al, Physics in Medicine and Biology, 43(5), 1998.



(a) Raw data (b) Processed data

Figure 2: Comparison between raw and processed mammogram images.

For the breast MRI, a semi-automated method was used to separate the breast region in the 3D dataset, and a clustering-based method was implemented to classify each voxel in fat or fibroglandular tissue. We used the MRI volumetric quantification as a gold standard to validate our model.

RESULTS: As a first result, the use of raw-data mammogram images allowed to reinforce the unreliability of the current qualitative estimation of breast density. Figure 2 shows the strong difference between a raw-data mammogram images with its correspondent processed images used for diagnosis.

We tested the accuracy of our geometric model for volume reconstruction. Figure 3 shows a high correlation ($R^2=0.986$) and small bias between the MR gold standard and the volume predicted by our model.