

# ASSESSMENT OF PANCREATIC ISLETS USING OPTICAL PROJECTION TOMOGRAPHY AND MAGNETIC RESONANCE IMAGING

JanakiRaman Rangarajan<sup>1,2</sup>, Ting Yin<sup>3,4</sup>, Josephine Gilbert<sup>5</sup>, Ashwini Atre<sup>3,4</sup>, Anna Eriksson<sup>5</sup>, Tom Dresselaers<sup>3,4</sup>, Frederik Maes<sup>1</sup>, Ulf Ahlgren<sup>5</sup>, and Uwe Himmelreich<sup>3,4</sup>

<sup>1</sup>ESAT/PSI - Medical Image Computing, KU Leuven, Leuven, Belgium, <sup>2</sup>iMinds-KU Leuven Future Health Department, KU Leuven, Leuven, Belgium, <sup>3</sup>Biomedical MRI unit, Department of Imaging and Pathology, KU Leuven, Belgium, <sup>4</sup>Molecular Small Animal Imaging Center (MoSAIC), KU Leuven, Belgium, <sup>5</sup>Umeå Centre for Molecular Medicine, Umeå University, Sweden

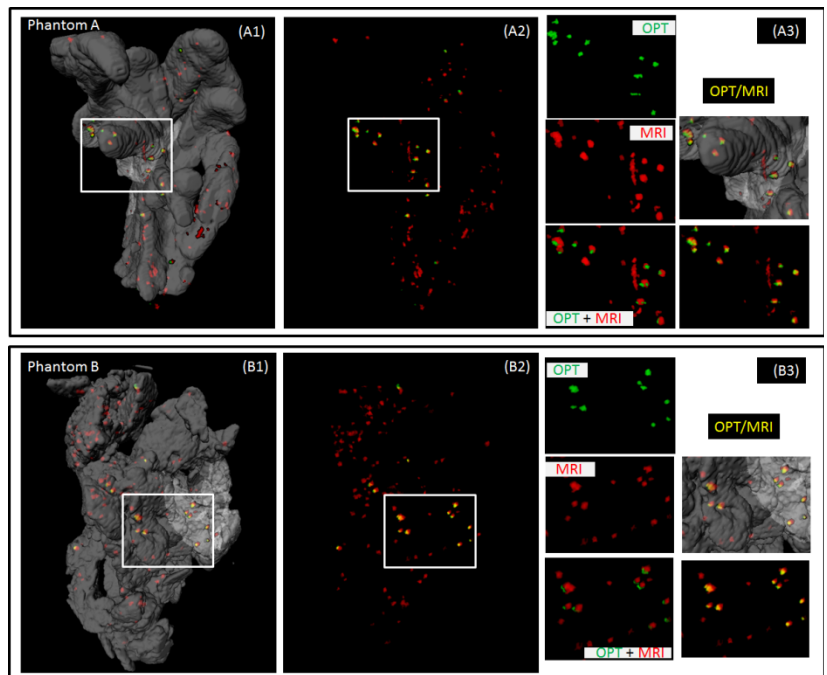
**INTRODUCTION:** Type 1 diabetes mellitus (T1DM) is caused by autoimmune destruction of insulin-producing beta cells of the pancreas. Islets graft transplantation has emerged as a potential strategy for T1DM treatment, but clinical studies show that the insulin independence rate decreased to 20% at 5 years post implantation [1]. Progressive islet loss drives the interest to study islet location and function *in vivo*. Non-invasive imaging methods may be used to monitor potential complications after transplantation. Hereby, the quantification of pancreas islets (PIs) mass is of great value for assessing islets graft loss post transplantation. MRI has become one of the most promising approaches due to its relative high spatial resolution, the capacity for longitudinal assessment, and non-ionizing radiation. The most widely used MR contrast agents for islets labeling are iron oxide based contrast agents, which generate hypo-intense signal in  $T_2$  and  $T_2^*$  weighted MR images [2]. However, the quantification of PIs in MR images is always challenging due to the false positive signal from other sources of hypo-intensity (blood vessels etc.). Alternatively, optical projection tomography (OPT) provides high resolution 3D images for non-fluorescent specimens and allows multi-spectral staining for different tissues/cell types that emit specific fluorescence signal. The use of OPT for pancreatic islets imaging has been recently demonstrated allowing quantitative assessment of the total islets distribution within different lobes of *ex vivo* pancreas (e.g. [3, 4]). Here, our objective is to cross-validate the labeled pancreatic islets as observed in the OPT and MR imaging. To this end, three-dimensional MRI and OPT images were acquired of pancreatic lobes that host PIs labeled with fluorescent tagged iron-oxide particles. Using spatial normalization methods, we co-registered the multi-modal data, which allowed co-localization of PIs using OPT and MR images in a 3D volume. We present the method for cross-validation of the MRI contrast, by using the high-resolution OPT images as gold standard.

**METHODS:** Pancreatic islets were isolated from mice and labeled with micron-sized iron oxide (MPIOs) particles (ME04F, diameter 1-1.99  $\mu\text{m}$ , BangsLab). Labeled islets were injected into a freshly isolated mouse pancreas. Pancreatic lobes were fixed and mounted in agarose prior to OPT scanning. Two sequential scans (one for pancreatic tissue (fluorescence channel), one for labeled islets) were performed on a Biophotonics 3001 OPT scanner (Biophotonics) using the following settings: rotation degree 0.9 degrees; pixel size 26.3x26.3  $\mu\text{m}$ ; resolution 1024x1024 pixels; exposure time 1000 ms. Subsequently, the phantoms were shipped to the collaborator site for MR imaging. MRI was performed on a 9.4T Biospec small animal MRI scanner (Bruker Biospec, Germany), using a quadrature transceiver volume coil with an extra gradient insert. Three-dimensional  $T_2^*$ -weighted gradient echo MRI (FLASH) were acquired using the following parameters: TR=100ms, TE=12ms, flip angle 20 degrees, spatial resolution=100 $\mu\text{m}$ (isotropic), matrix=160x320x160, 6 averages. In order to co-localize the labeled islets in OPT and MR images, high-resolution 3D OPT tissue images were spatially normalized to the corresponding 3D MR images. After manual re-orientation and initialization to approximately overlay the multi-modal data, a 12-parameter affine transformation was determined automatically by maximizing mutual information [4], between MRI and OPT tissue images. This allowed visualization of MRI and OPT volumes as 3D overlay, in either MRI or OPT image space. In order to quantitatively assess the PIs, we segmented the hypo-intense clusters based on connected component analysis on intensity threshold MRI and OPT images. The minimum cluster size was set to 2 voxels (in MR image space) and the intensity threshold was adjusted such that almost all of the islets identified in OPT images were co-localized in corresponding MR images. The number of clusters identified in each of the modalities individually were determined, as well as those which were co-localized. By considering OPT as gold standard, the false negatives (found only in OPT, but not in MRI) and false positives (found only in MRI), were also reported. The resulting cluster of PI's identified in OPT and MRI were rendered and color coded.

**RESULTS:** Qualitative visualization of PI's from OPT and MRI are illustrated from two representative phantoms A and B (see Figure). Quantitative measures corresponding to individual and co-localized clusters are summarized in the Table. The 3D rendering of pancreatic tissue (from OPT scans), is overlaid with cluster of voxels segmented from MRI (hypointense, in red) and OPT channel (islets channel, in green). The co-localized clusters are illuminated in yellow color. The magnified views present the extent of co-localization. The number of clusters measured in OPT, nearly match the actual number of labeled islets within the pancreas. The islets that were not noted in our OPT quantification, were either outside the pancreas or were not part of the mask within which the quantifications were computed. Quantification of overlap between signals from OPT with MRI showed about 90% agreement of OPT signals with corresponding MRI signals. Approximately 85% of MRI signals did not overlap with an OPT signal, indicating large numbers of false positive signals in FLASH MR images. The accuracy of OPT/MRI co-registration were qualitatively assessed at multiple cross-section and deemed appreciable for co-localization needs of this application.

**DISCUSSION & CONCLUSION:** We have demonstrated the cross-validation of PI assessment using MRI, by spatially aligning the 3D multi-modal pancreatic images from OPT and MRI and objectively assessing clusters of labeled PI's. While the clusters correspond between OPT and MRI, the large number of false positives in MRI is likely explained by air bubbles resulting from the phantom preparation. But this would not be an issue for future assessment of *in vivo* MRI studies. In conclusion, successful co-registration of PIs from MRI and OPT images allowed cross-validation of MR images, confirming its suitability for *in vivo* PI imaging. This is an essential prerequisite for future validation of *in vivo* MRI data using beta-cell targeting iron oxide based nanoparticles.

**REFERENCES:** (1) Gavin Low, 2010.; (2) T. Alanentalo, et al. 2007; (3) A. Hörnblad, 2011. (4) F Maes, et.al. 1997.



**Figure:** Co-localization of pancreatic islets in OPT (green),MRI (red). Overlay (yellow)

	Labeled	OPT	MRI	Co-localized	False -ve	False +ve
Phantom A	21	20	107	18	2	89
Phantom B	22	16	122	15	1	107